


Two HIV-infected Adolescents with Skin Lesions

Dr Dawn Balang

Dr Clementine Khumalo

Dr Memory Bvochora-Nsingo



17 year old male patient

- Diagnosed with HIV infection in 2010
- Commenced HAART 2010
- Currently on second –line Atazanavir/ Ritonavir 300/100 mg od
- Issues with compliance to HAART
- History of chronic severe Otitis media



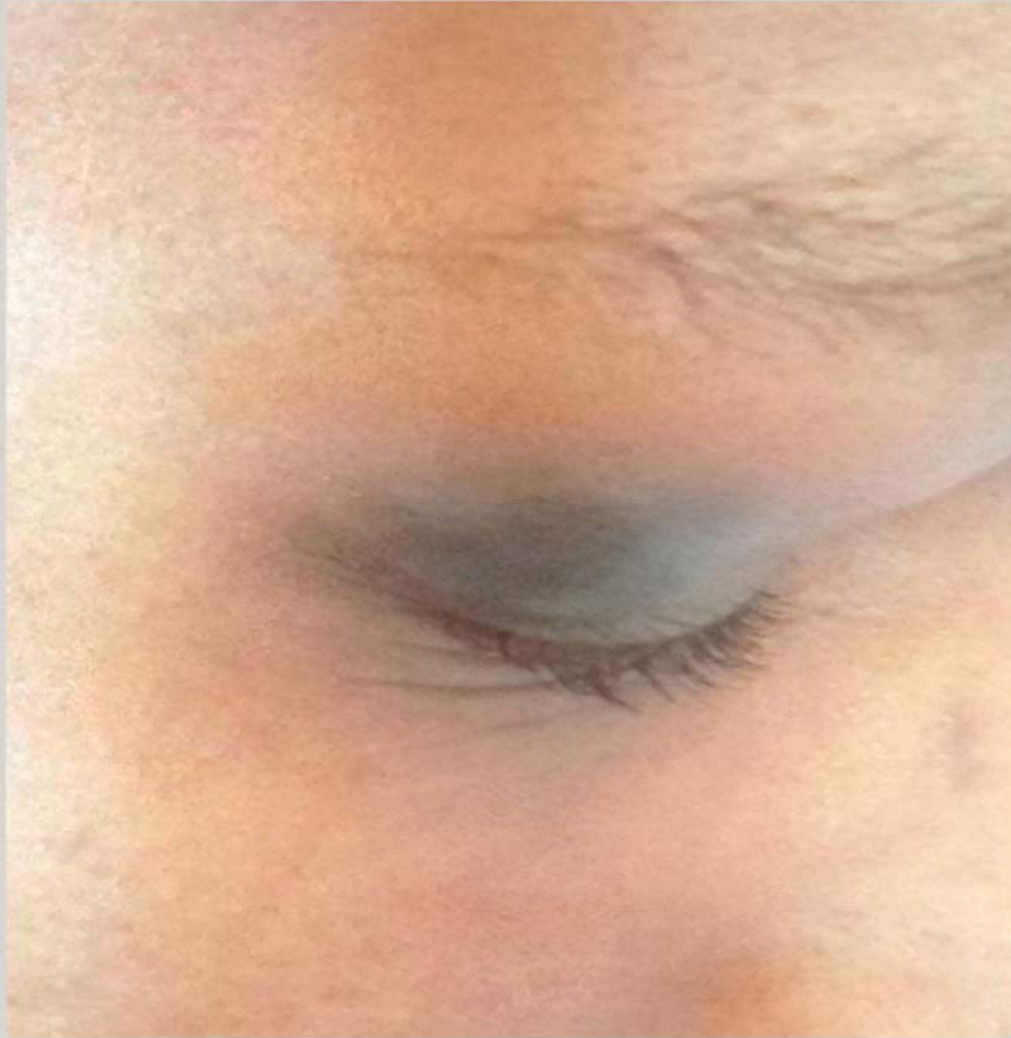Mstr BR, 17 year old

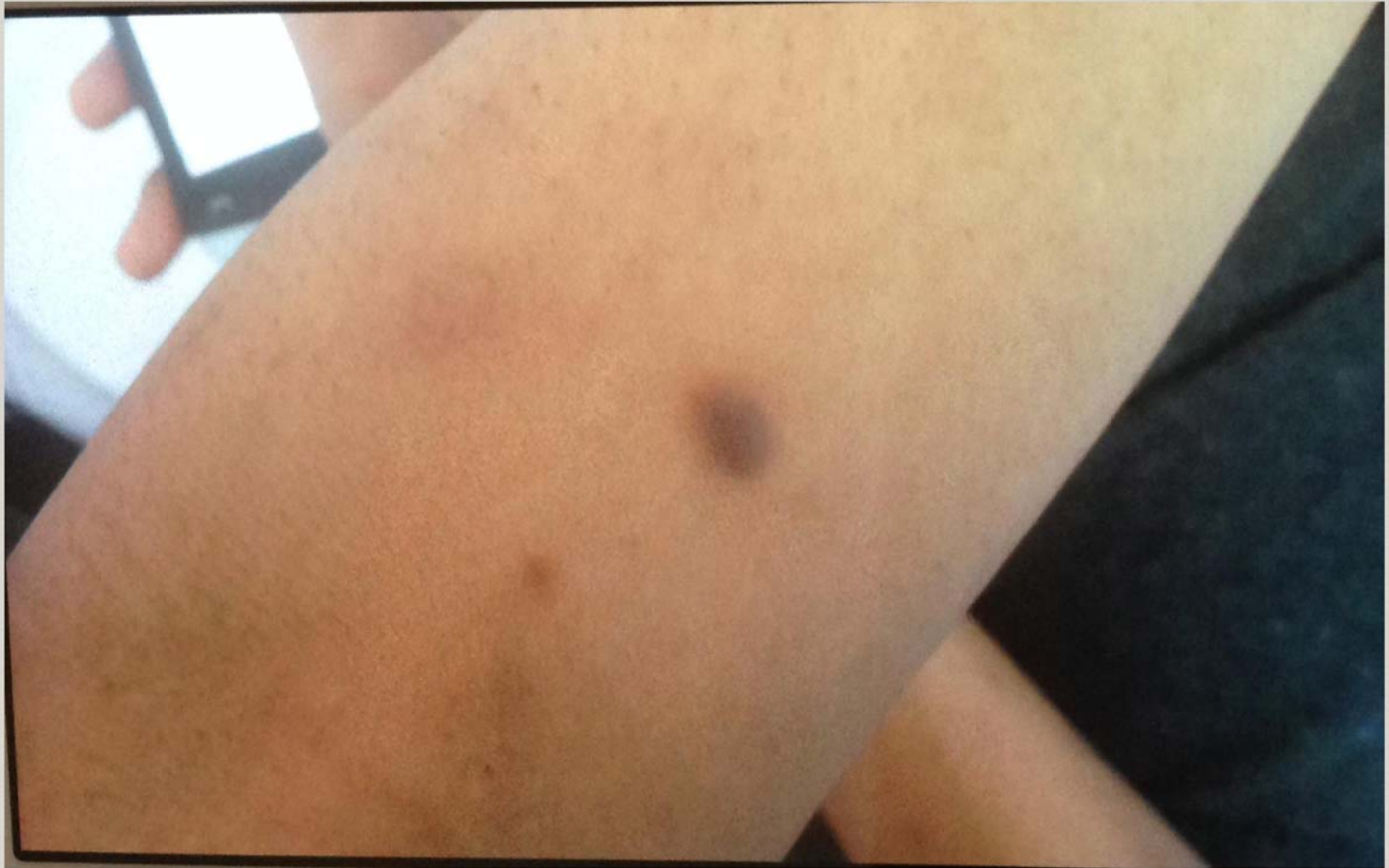- Referred by GP as an emergency to oncologist in August 2015
- 2 month history of:
 - dry cough associated with central chest pain
 - decreased appetite → 4 kg weight loss
 - recurrent fevers & night sweats
 - frequent vomiting
 - frequently absent from school due to illness
- Pigmented lesions over eyelids and torso



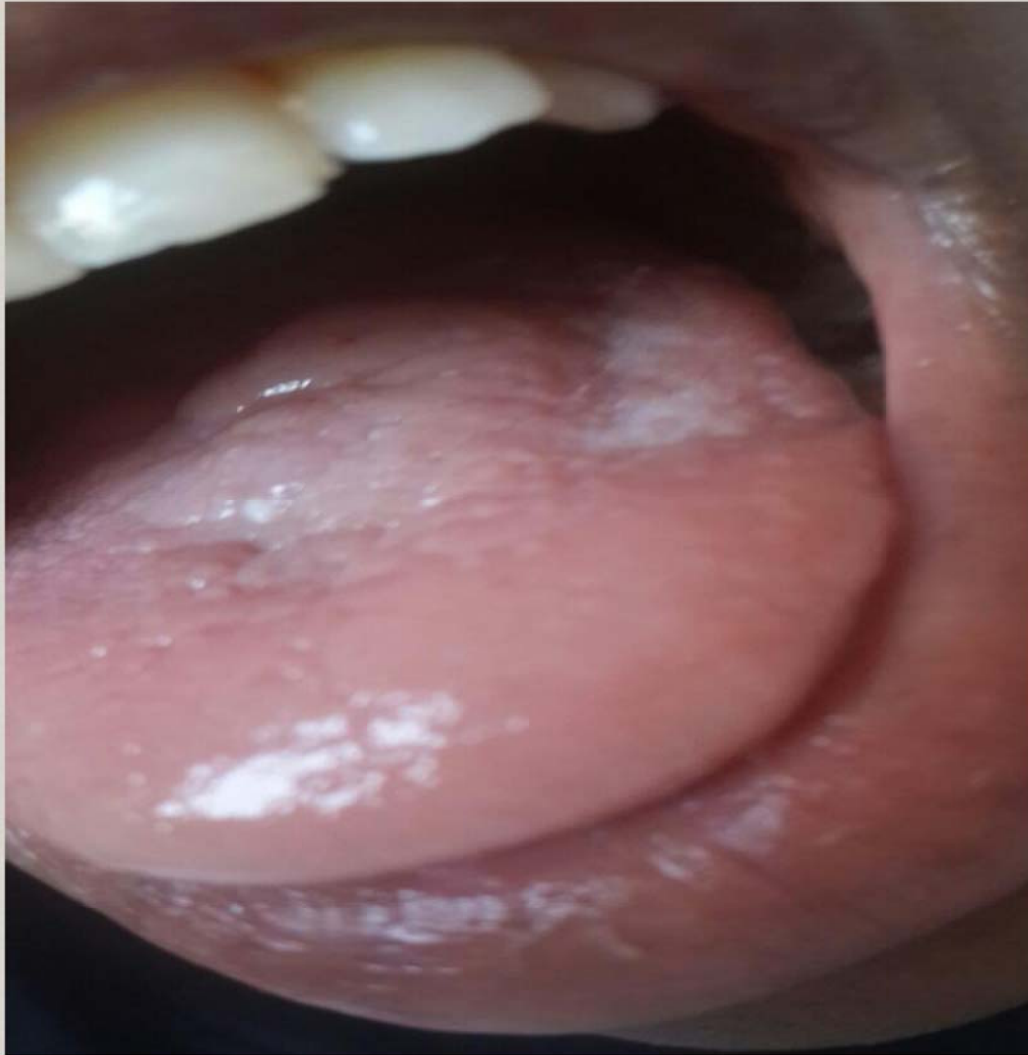- Ill-looking & lethargic
- Comfortable on room air
- Disseminated pigmented lesions; especially eyelids and chest







Hairy leukoplakia and tongue hyperpigmented lesions

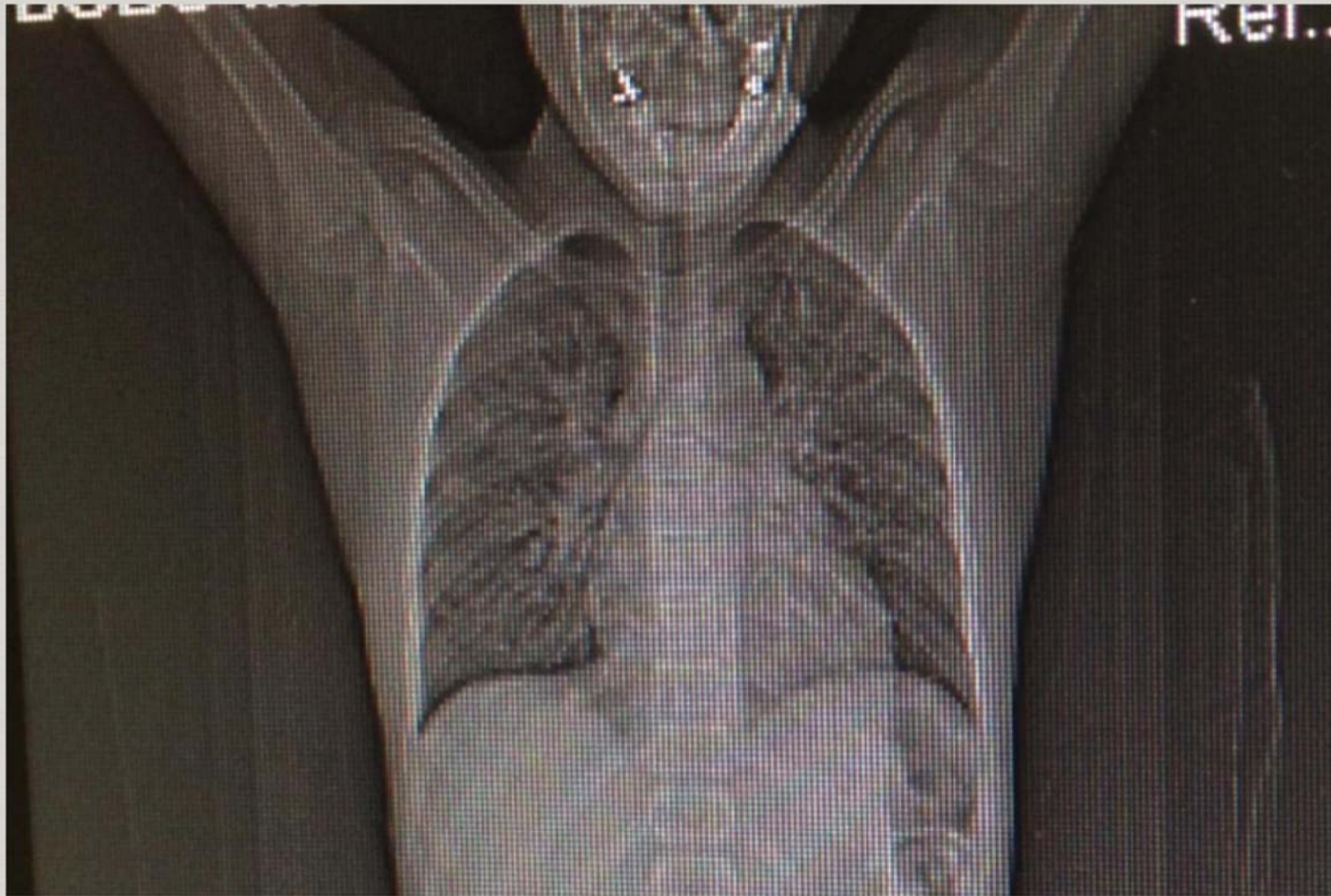

Examination cont..

- Chest – decrease air entry globally
- No wheezes or crepitations
- Abdomen-organomegally / masses
- No palpable lymphadenopathy



CXR



Blood Tests

- Hb 3.6 g/dl
- Plt 385
- WCC $5.07 \times 10^9/l$
- Creat 40 $\mu\text{mol/l}$
- Urea 4.0 mmol/l
- Normal LFTs
- Sputum sent for AFB



Monitoring [whole Blood]

Test	Result	Normal Range	Last Result
------	--------	--------------	-------------

HEMATOLOGY

MONITORING

TOTAL T - CELLS CD3	720	cells/uL	1756
600 - 2500 Please note: There are no Botswana established ranges for CD3. The quoted ranges are predominantly from Europe and North America			

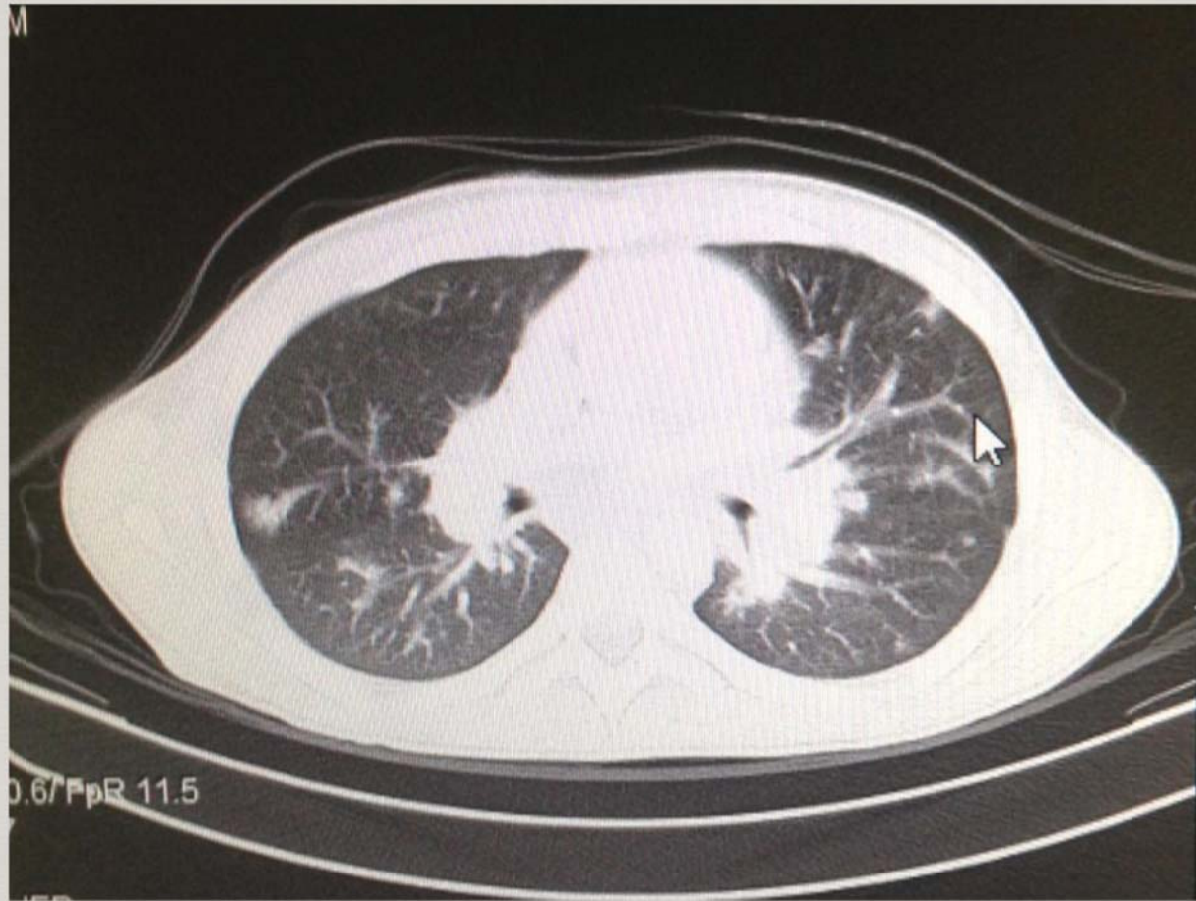
CD 4	40	cells/uL	LO (374 - 1527)	53
CD 4%	2.51	%	LO (29 - 57)	1.85
CD 8	596	cells/uL	(225 - 1053)	1567
CD4 : CD8	0.07	-	LO (0.79 - 2.88)	0.03

Please note change in CD4, CD4%, CD8, and CD4:CD8 ratio
Flowcytometry ranges effective 1 July 2014.
These are the established ranges for Botswana

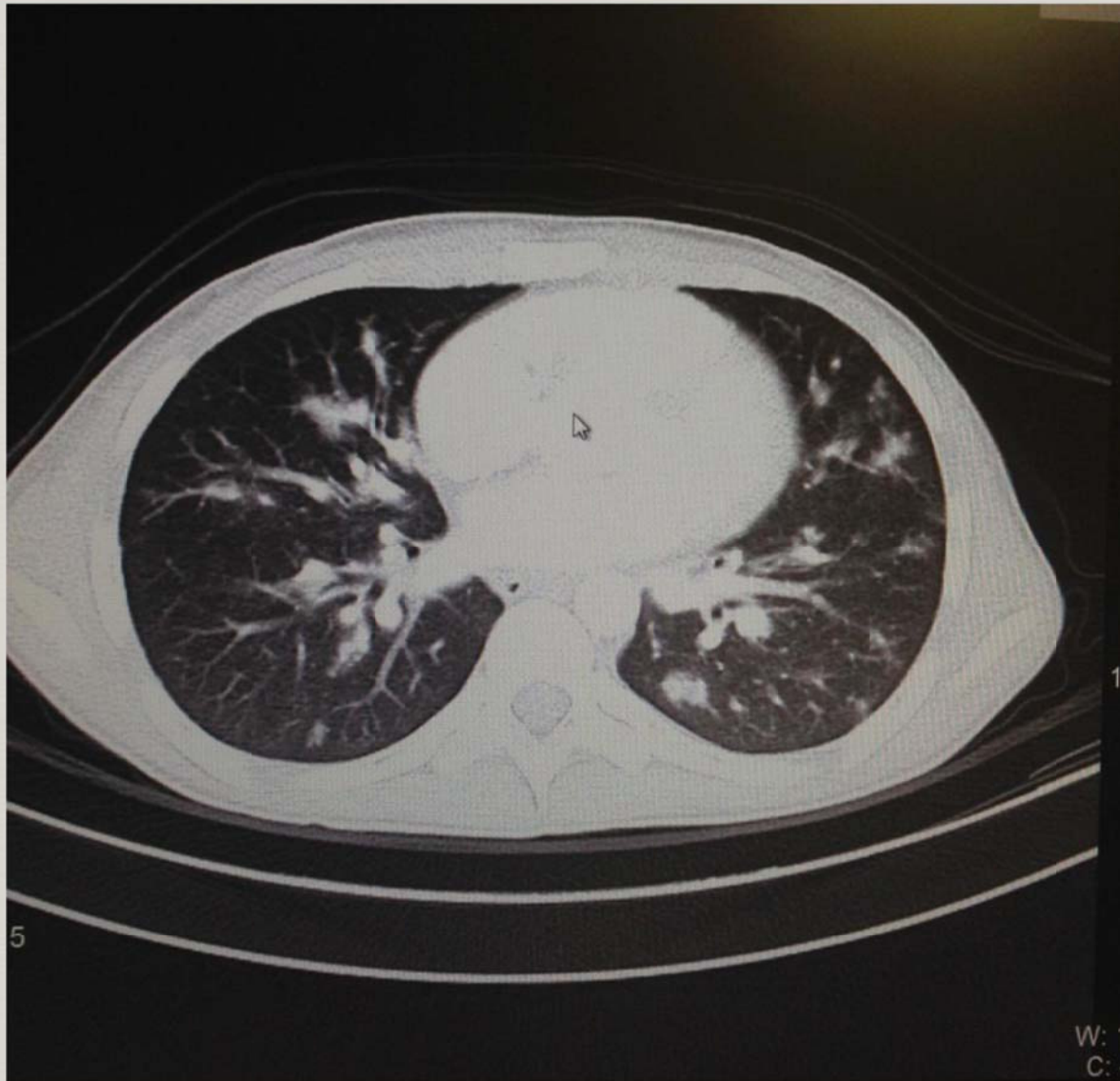
VIRAL LOAD	31000	copies/ml	45000
VIRAL LOG	4.49	-	4.65
VIRAL INTERPRETATION	Positive	-	Positive

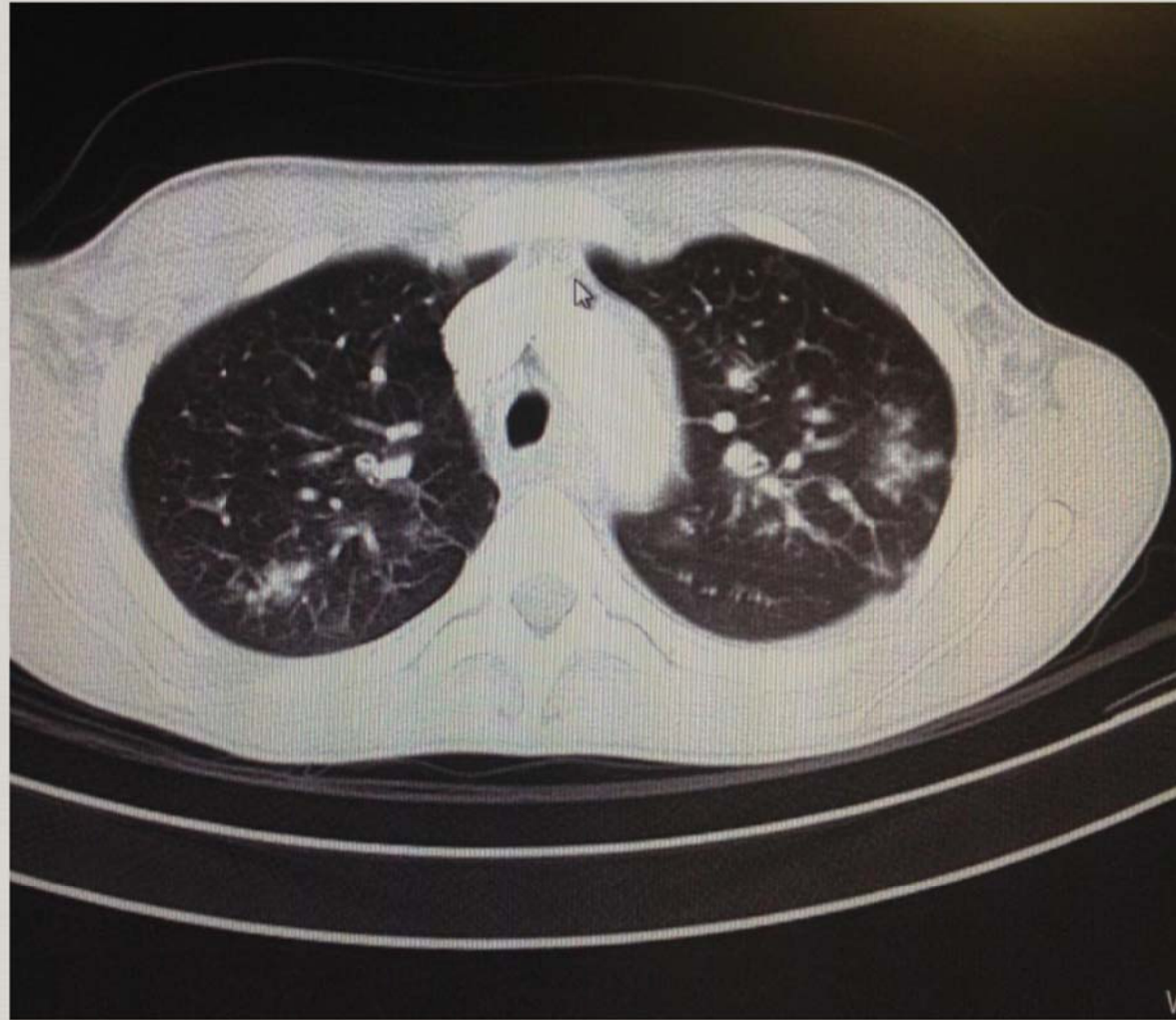


CT Chest

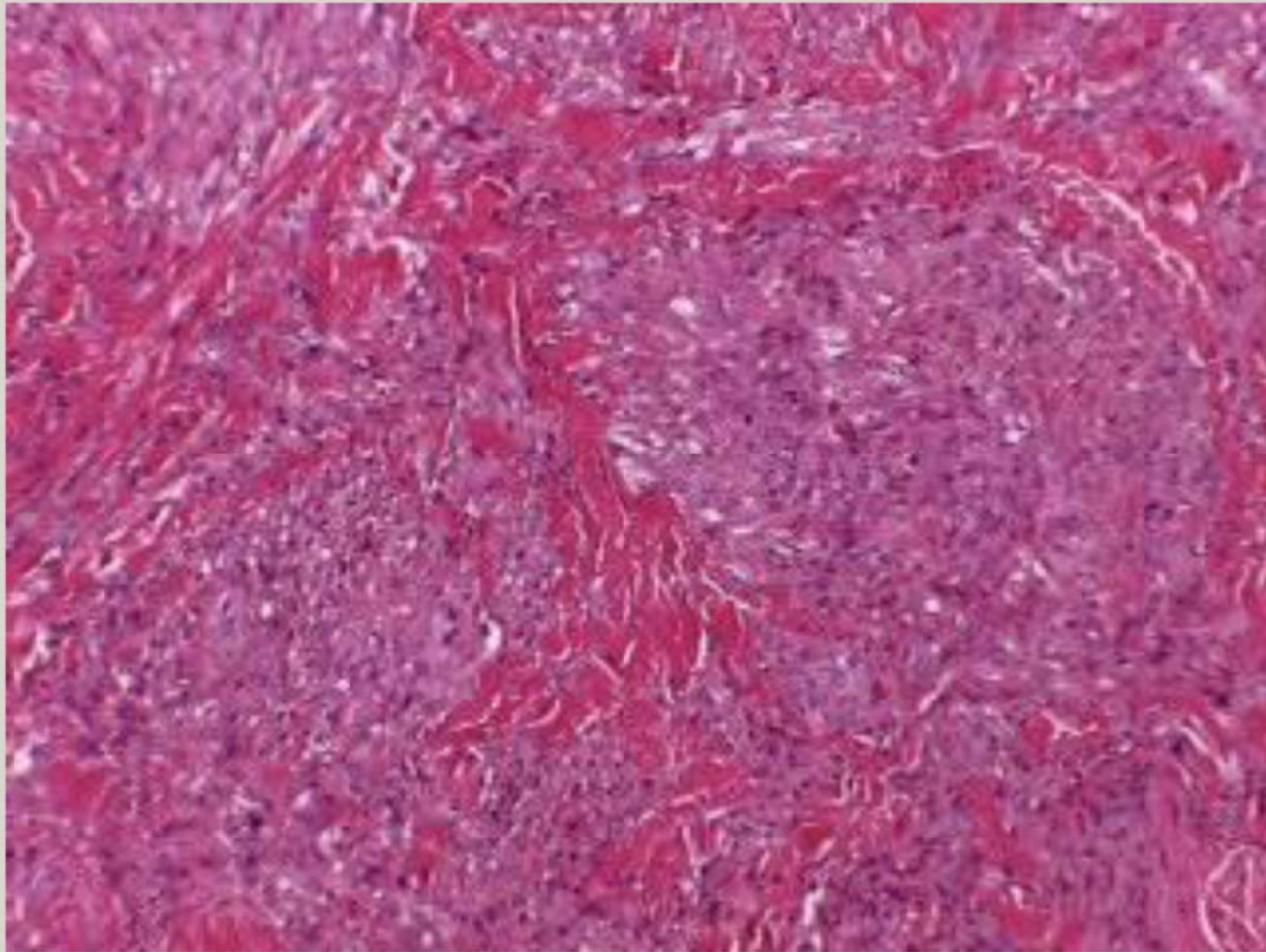


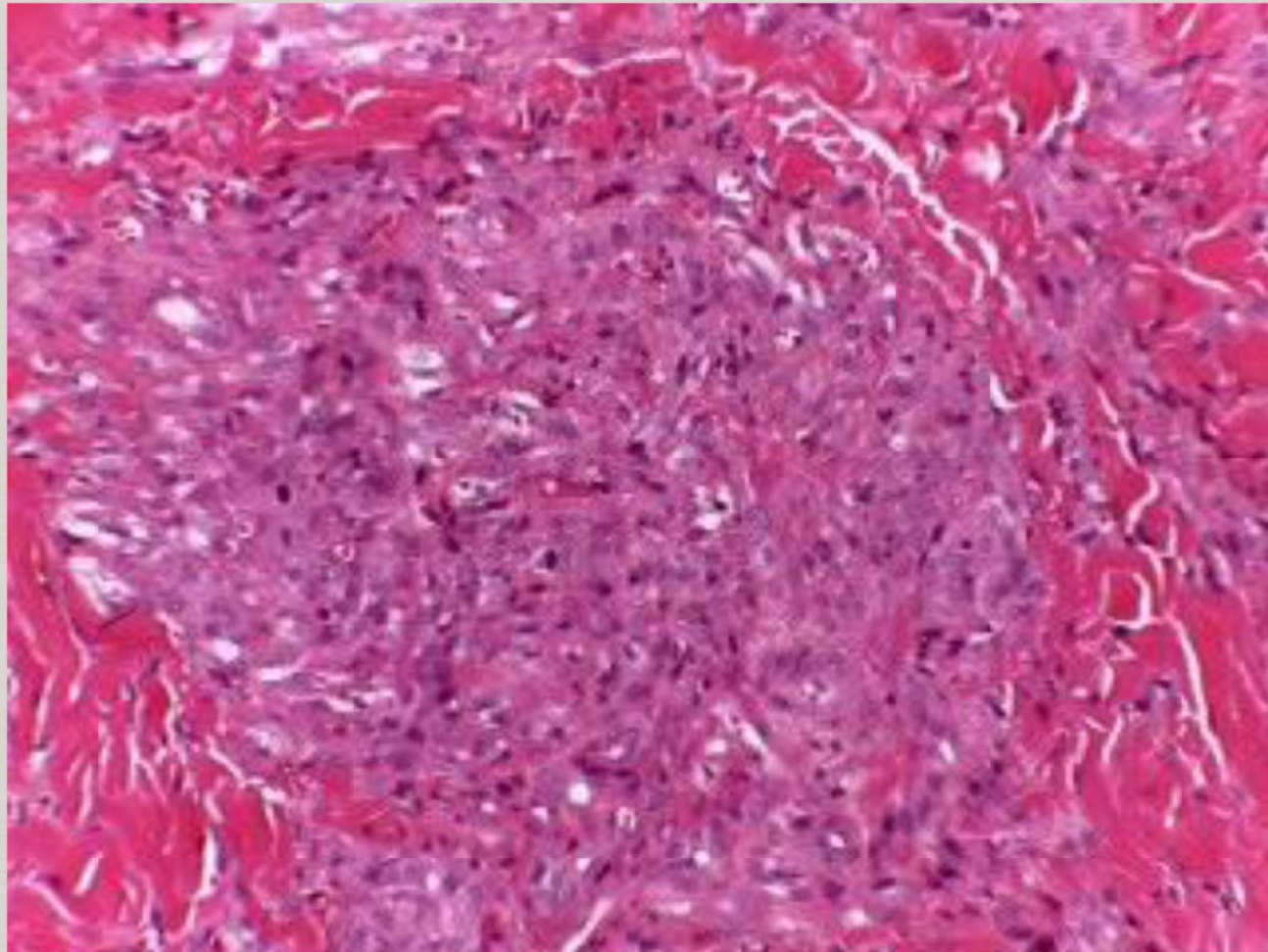
CT chest

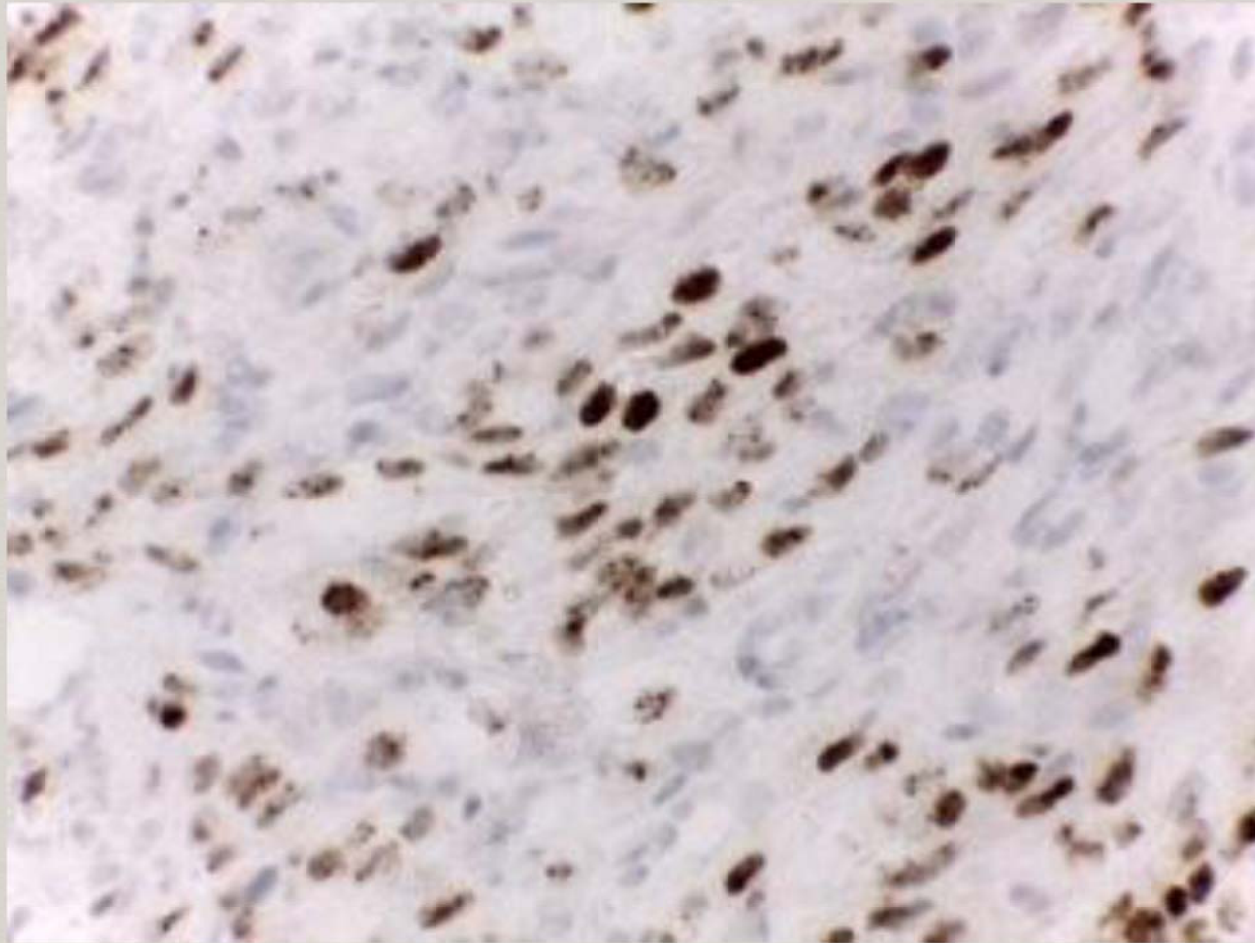




Pathology







Management

- Transfused 4 units of packed cells
- -Hb → 8.9 g/dl
- Physician consulted to ensure compliance with HAART
- Started on chemotherapy
 - -Bleomycin 15 iU/m² (dose 20 mg)
 - -Vincristine 1.4 mg/m² (dose 2 mg)
 - - Every 3 weeks ; so far has had 4 cycles



Currently...

- Has had four cycles of chemo so far
- Doing well- skin lesions smaller & flatter
- Constitutionally well
- Recently had repeat chest Xray



Chest Xray November



O.M.

- 15 year old male patient
- Early 2015 – black spots on the thighs and groin
- Seen by GP– tested HIV positive , baseline CD4 Ct-22
- Commenced on Tenofovir/Emtracitibine/Efavirenz
- Seen by a specialist physician , referred to surgeon – Biopsy done in October



O.M.

- PSHx - nil
- PMHx – uneventful, normal growth and developmental milestones, no antenatal HIV testing , no PMTCT
- Medication Hx - No known drug allergies
- Social Hx - No history of drinking or smoking, stays with mother who is widowed, tested HIV positive (when index patient was 4 years old) and is on HAART

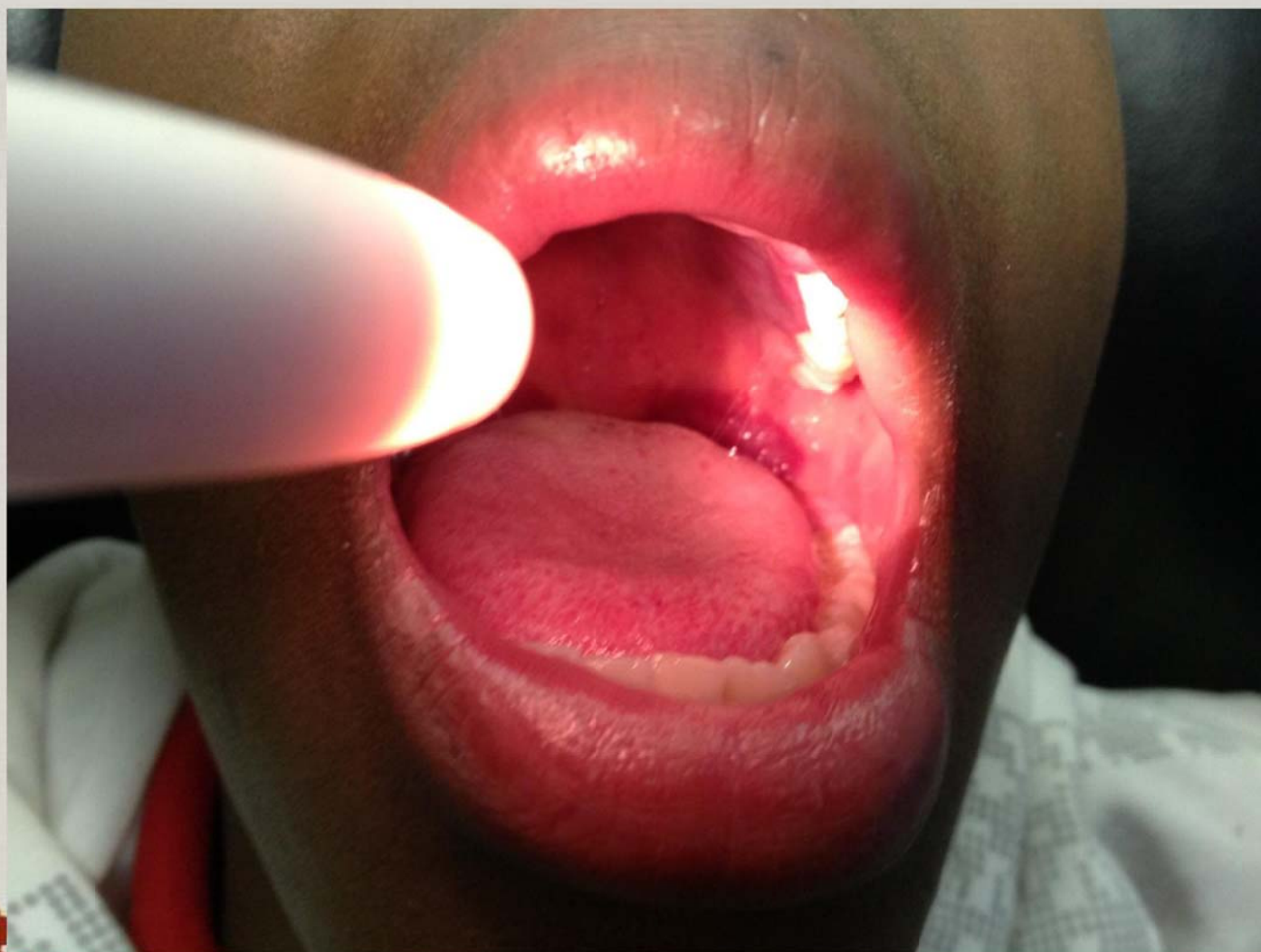


O.M.

O/E

- Performance Status 1
- slim
- no pallor/jaundice/pedal oedema
- palatal KS lesions noted
- chest-NAD
- abd-NAD
- skin - generalised hyperpigmented macular lesions

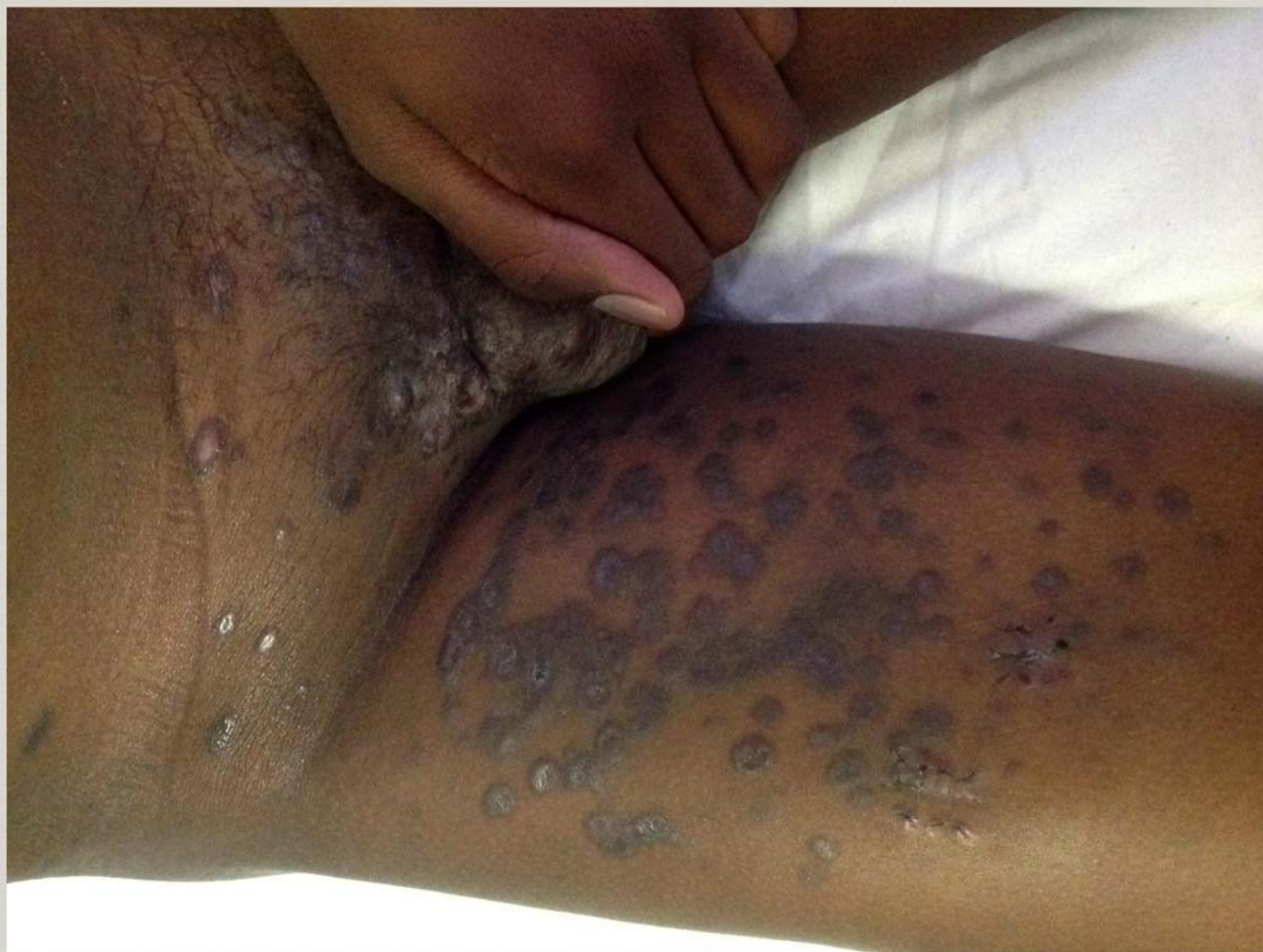



O.M.

- Hyperpigmented macules and plaques on the pubis and upper thighs- some involvement of the genitals
- Bilateral inguinal lymphadenopathy conglomerate ~ 5x3cm



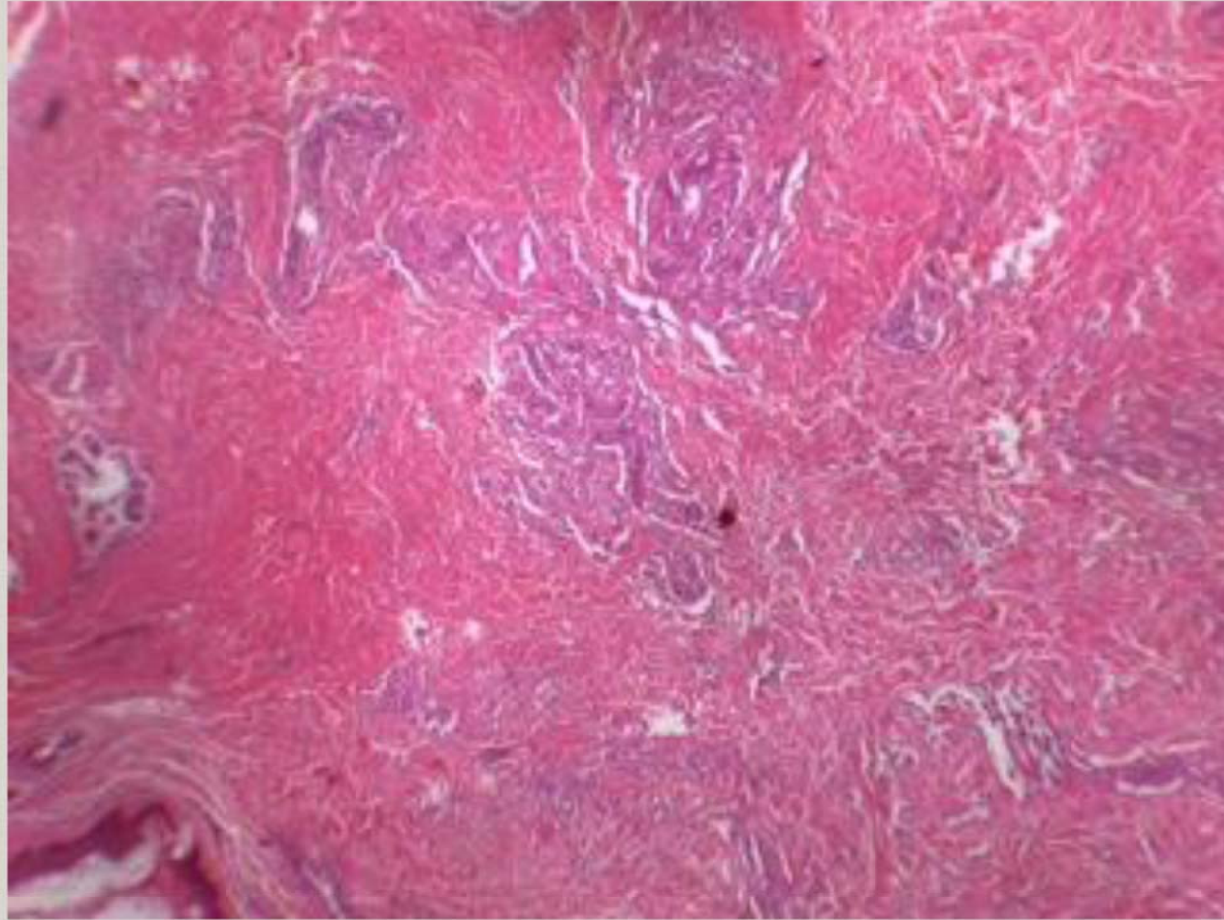


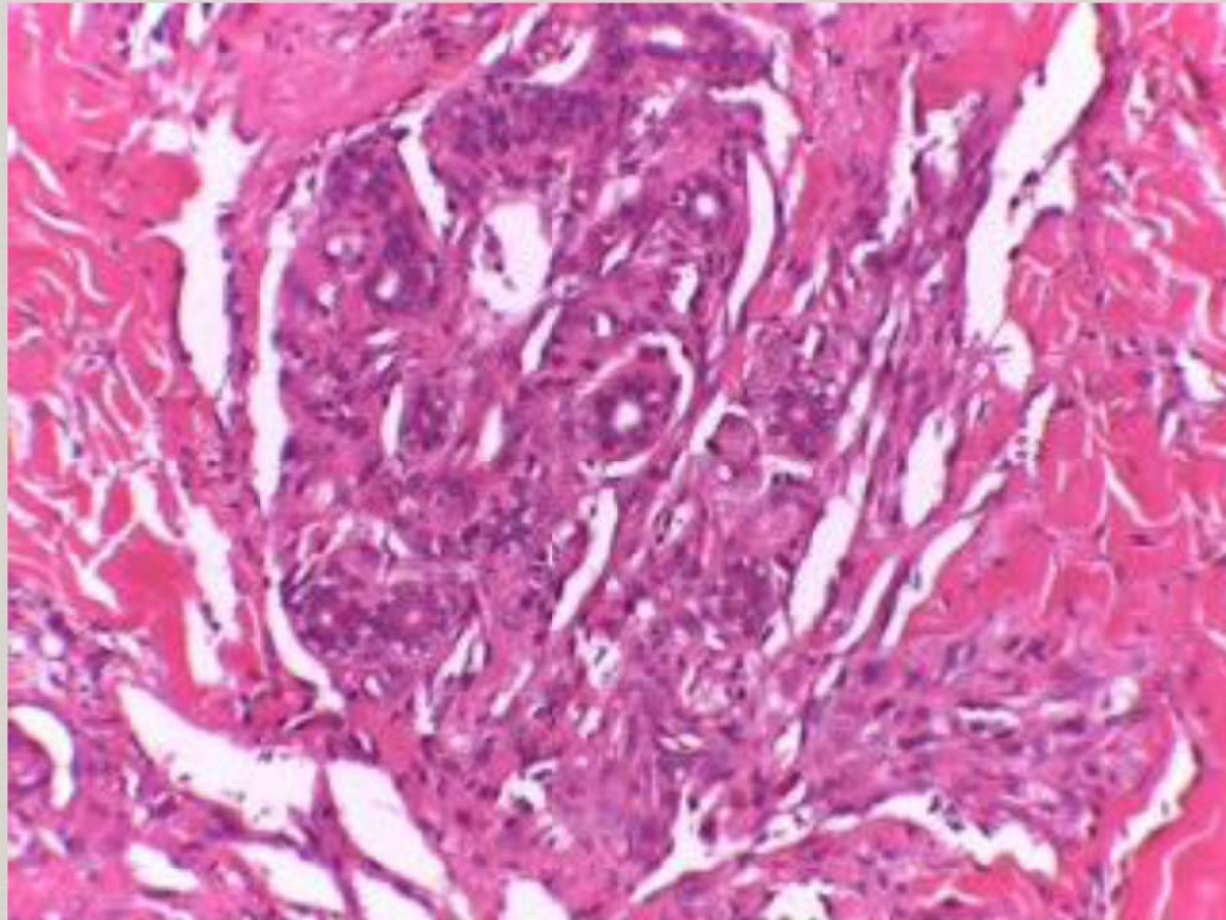
RESULTS

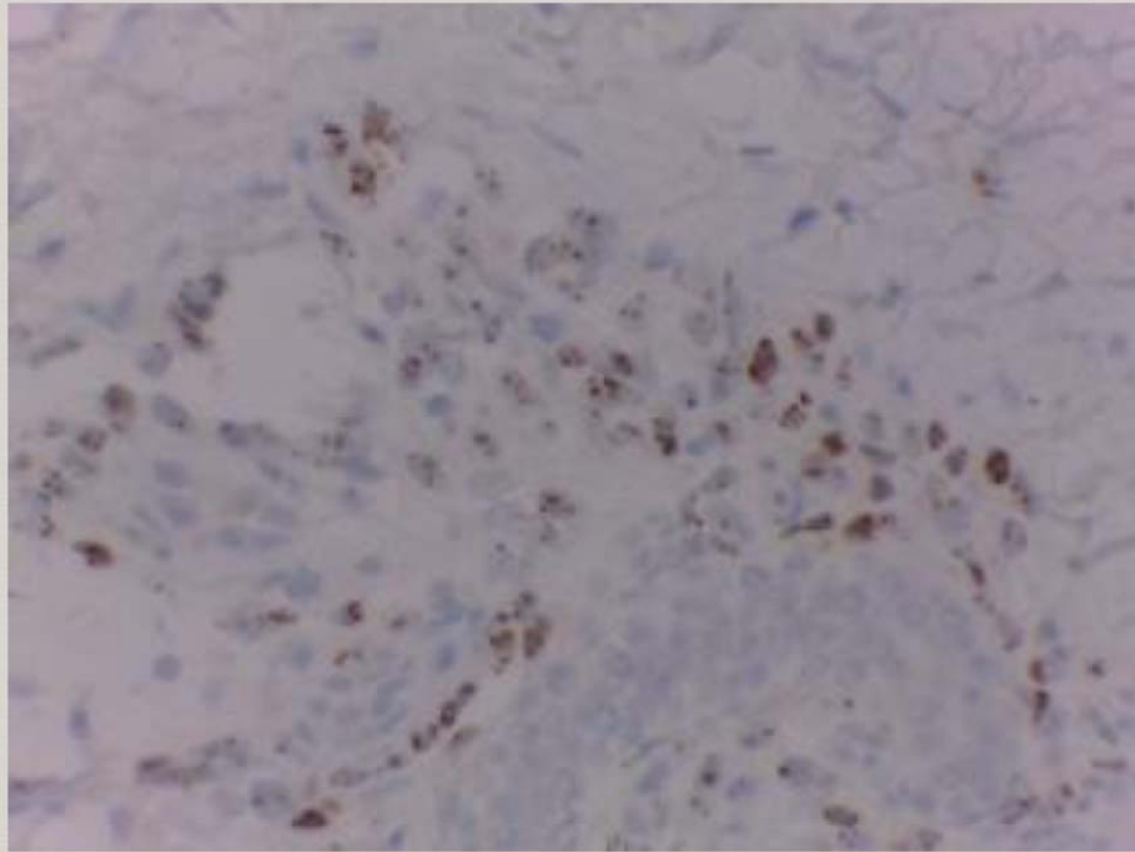
- Biospy – [REDACTED]/10/2015 – Kaposi's Sarcoma
- USS abd/pelvis - [REDACTED]/10/2015 – ill-defined hyperechoic mass in the liver-2.7X2.3CM, coarse echotexture of spleen, liver.



Pathology







Blood Results



Guarantor : BMD-Bomaid

Received at lab :

Full Blood Count [whole Blood], Monitoring [whole Blood],

Test	Result	Normal Range	Last Result
MONITORING			
CD 4	22 cells/uL	L O Result checked	22
	Result checked		
CD 4%	1.85 %	L O (29 - 57)	1.79
CD 8	579 cells/uL	(225 - 1053)	535
CD4 : CD8	0.04 -	L O (0.79 - 2.88)	0.04
Please note change in CD4, CD4%, CD8, and CD4:CD8 ratio Flowcytometry ranges effective 1 July 2014. These are the established ranges for Botswana			
VIRAL LOAD	750 copies/ml		160000
VIRAL LOG	2.88 -		5.20
VIRAL INTERPRETATION	Positive -		Positive

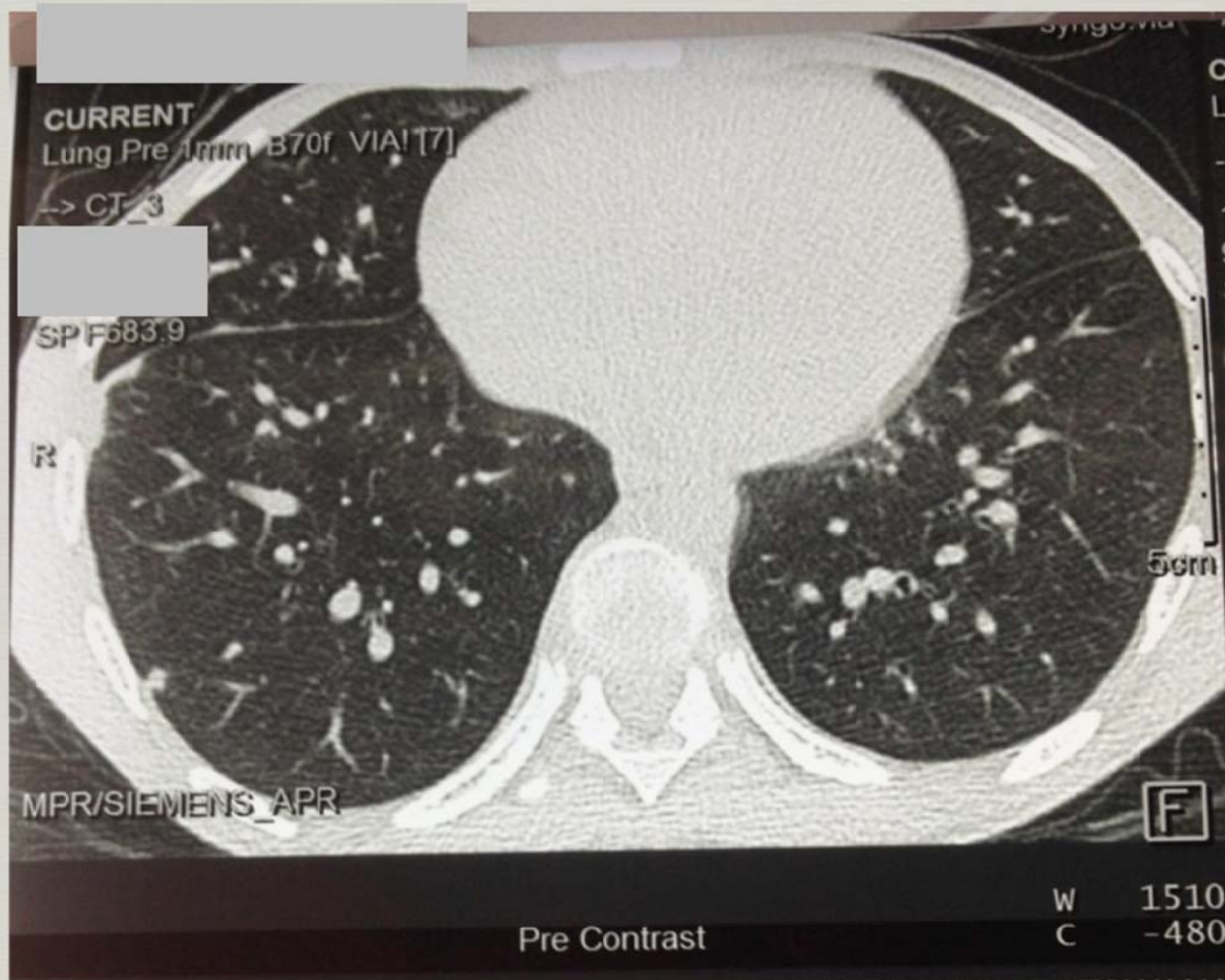

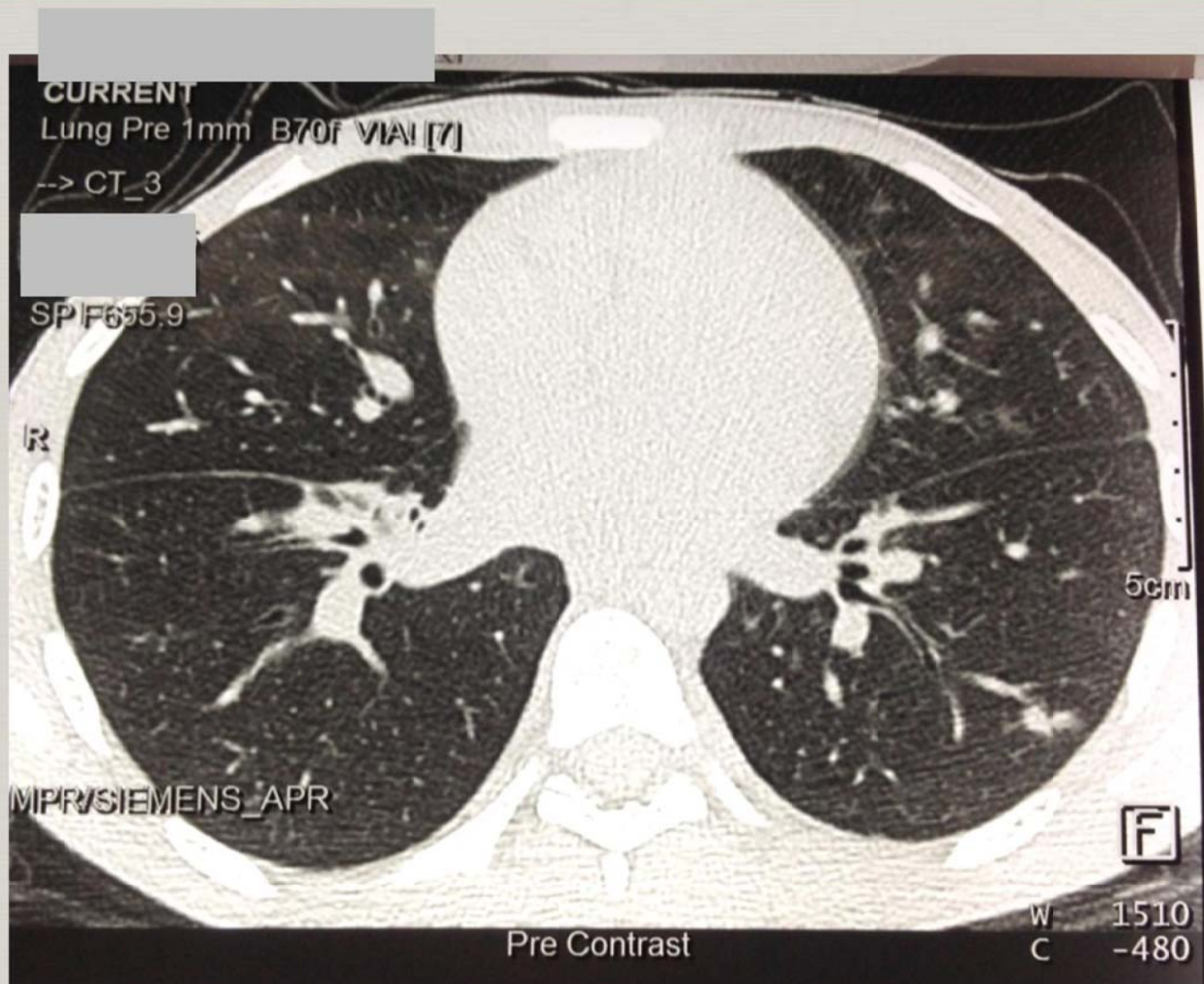
O.M.

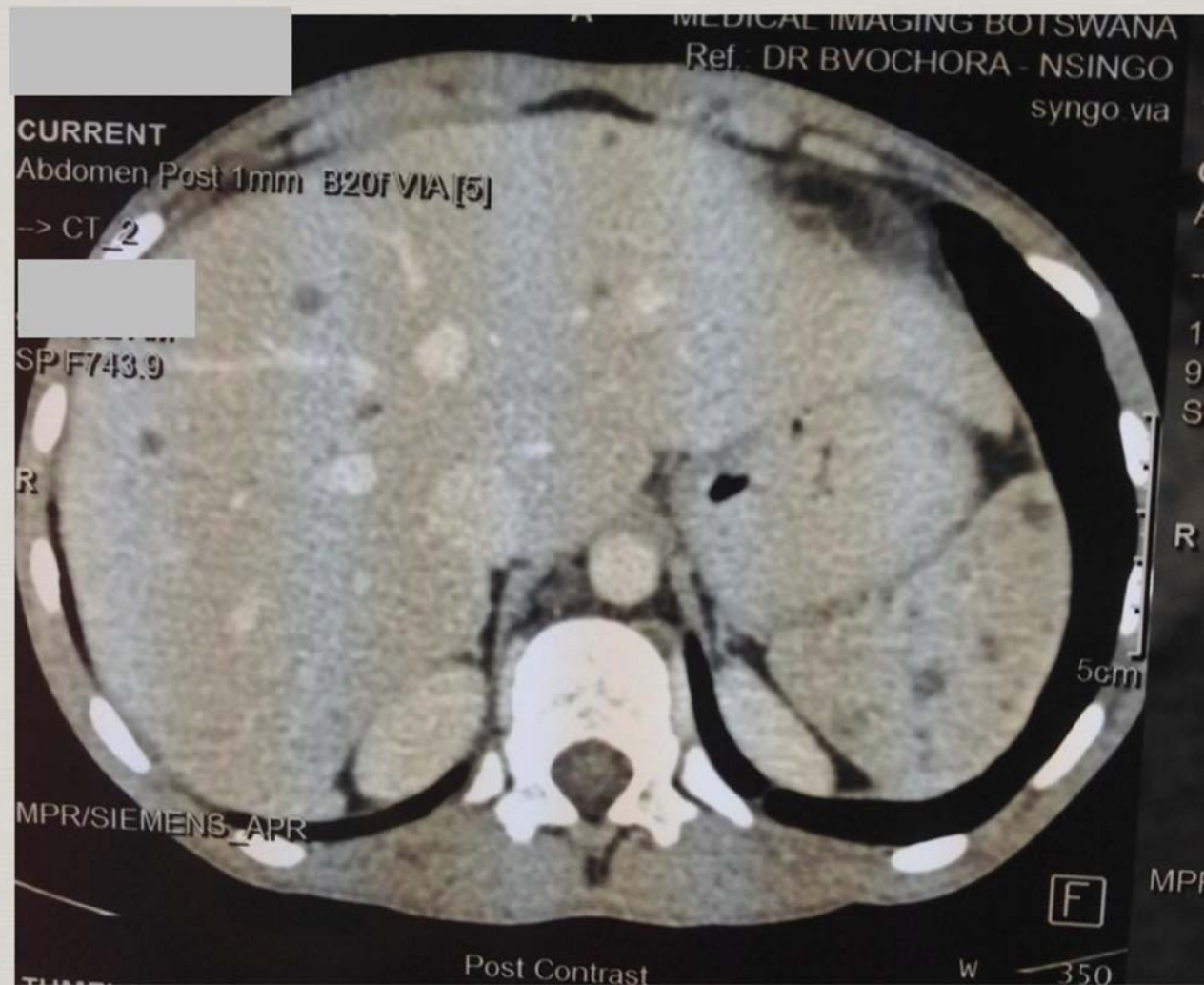
CT SCAN ABD – [REDACTED]/11/2015

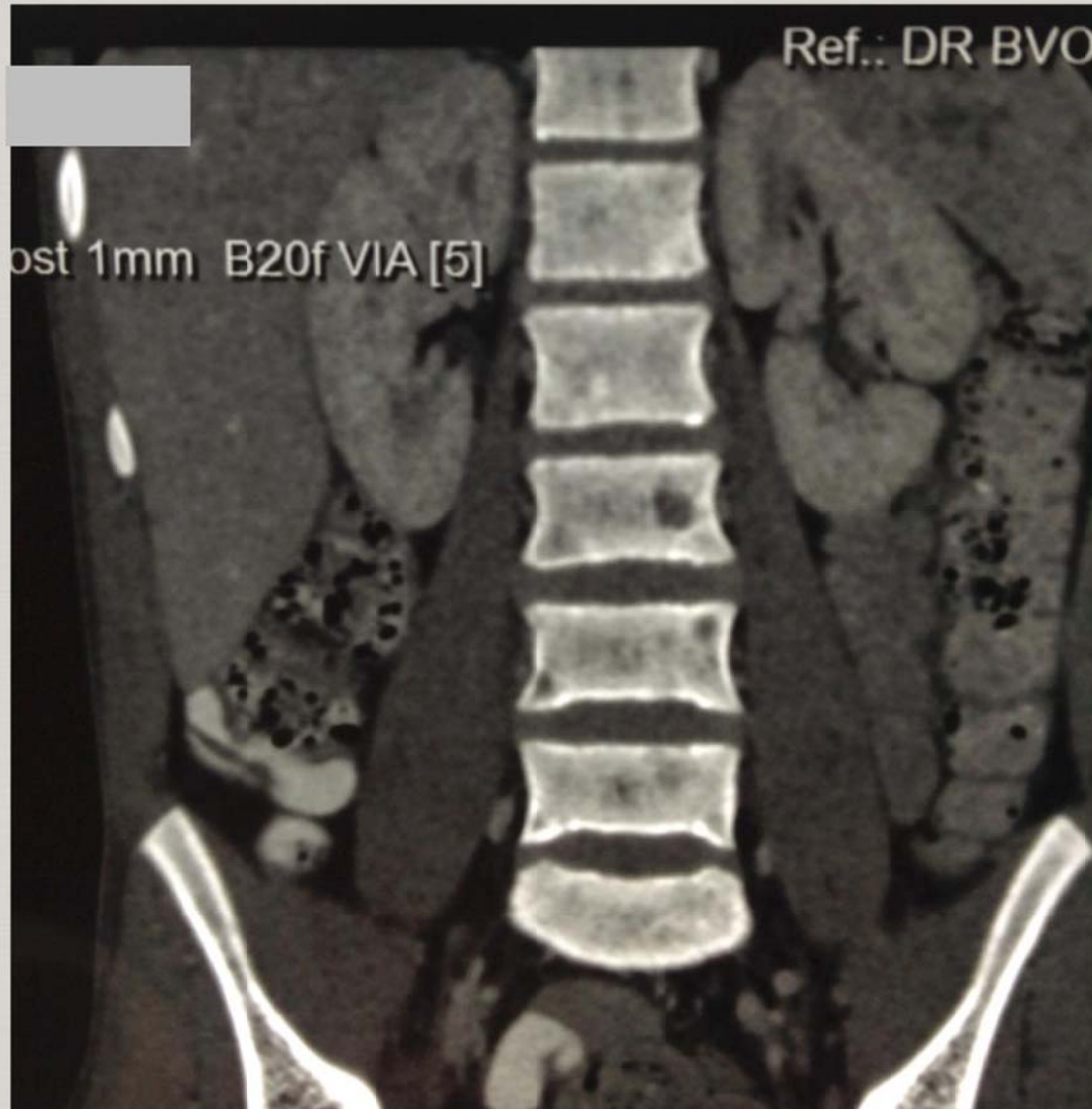
- 1) Nodular shadows lower lung fields
- 2) ?scar + pleural fluid in horizontal fissure
- 3) Numerous low density lesions in the liver
- 4) Extensive low density lesions in the spleen
- 5) Diffuse lytic changes mostly in vertebral bodies and pelvis
- 6) Medium sized nodular shadow-rt groin

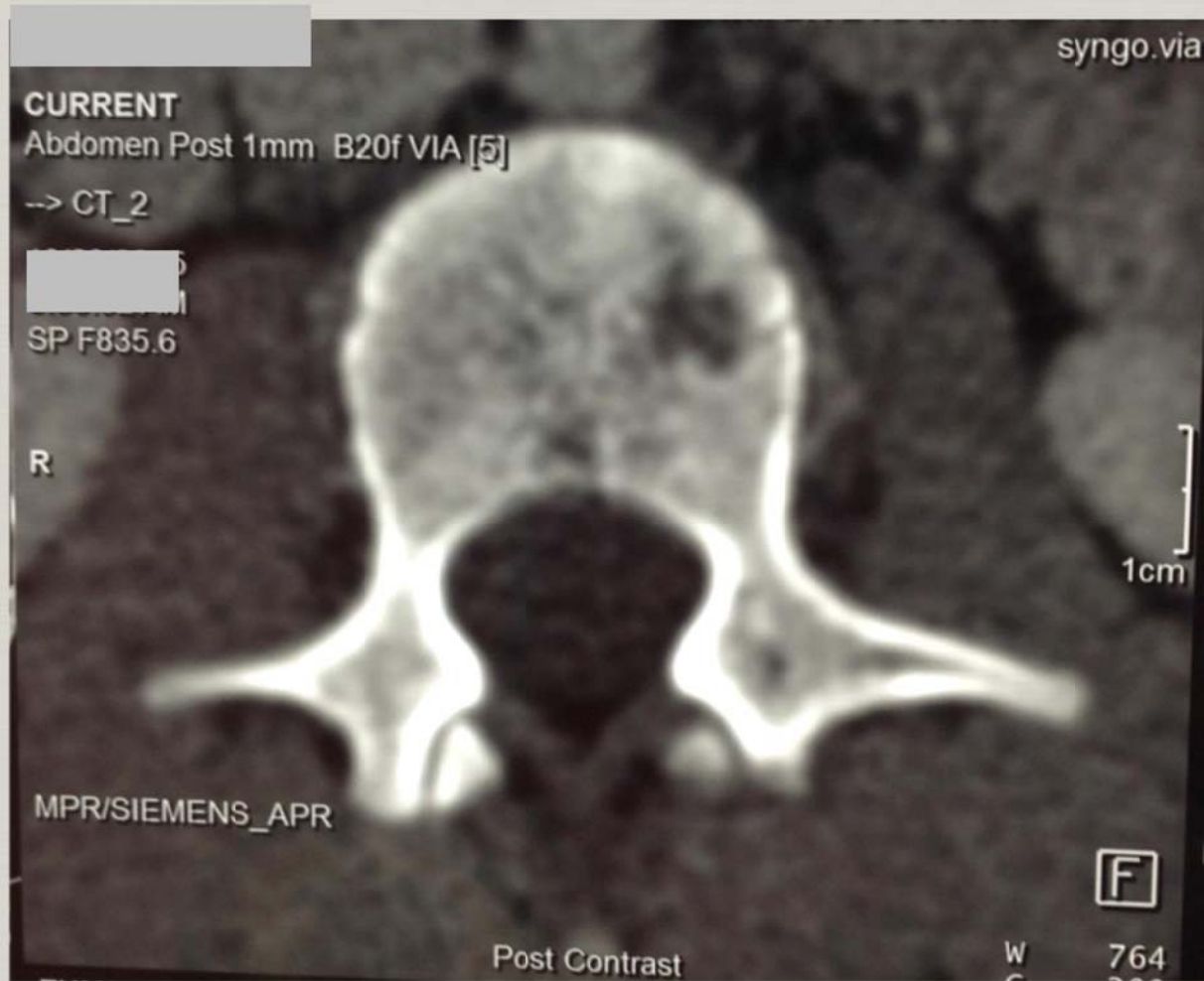


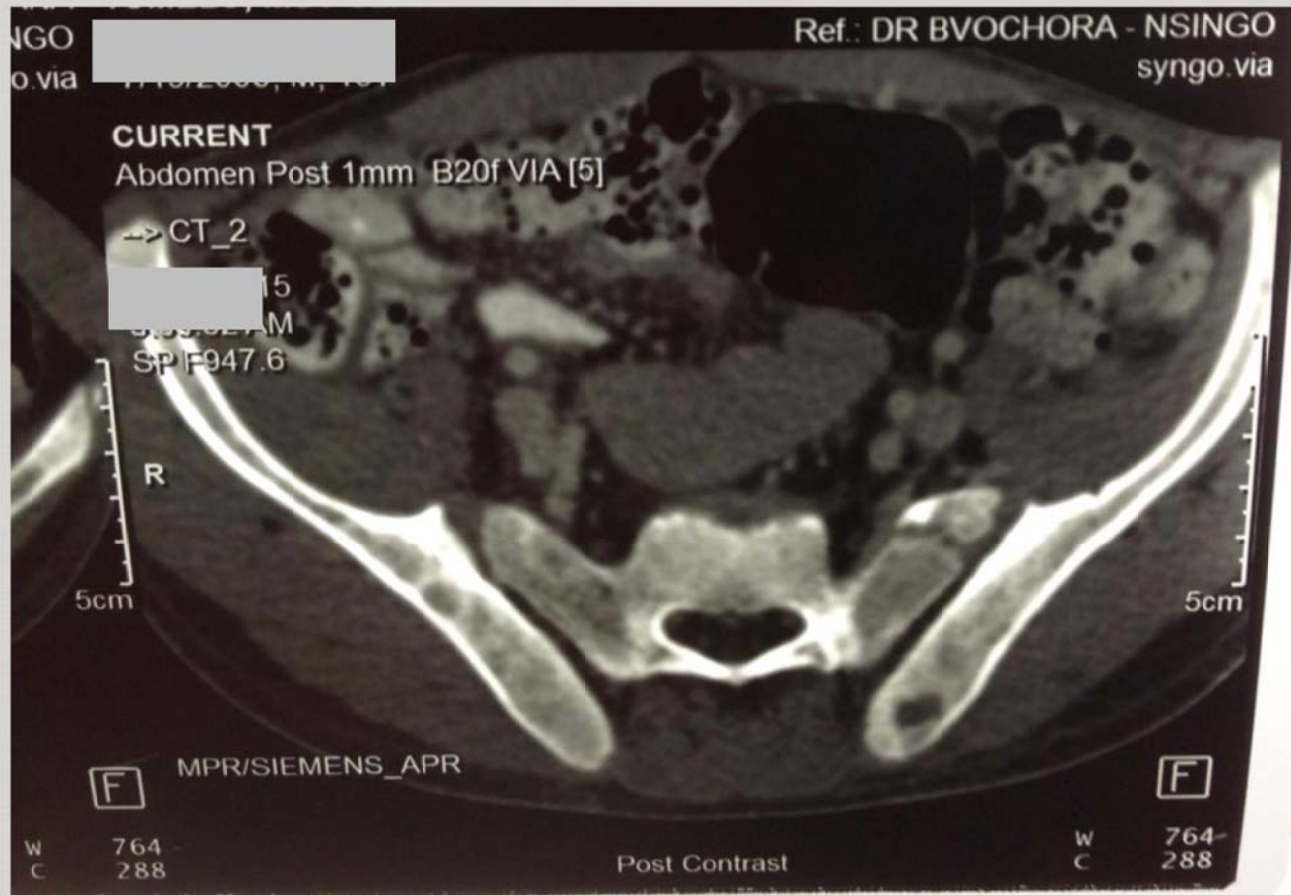


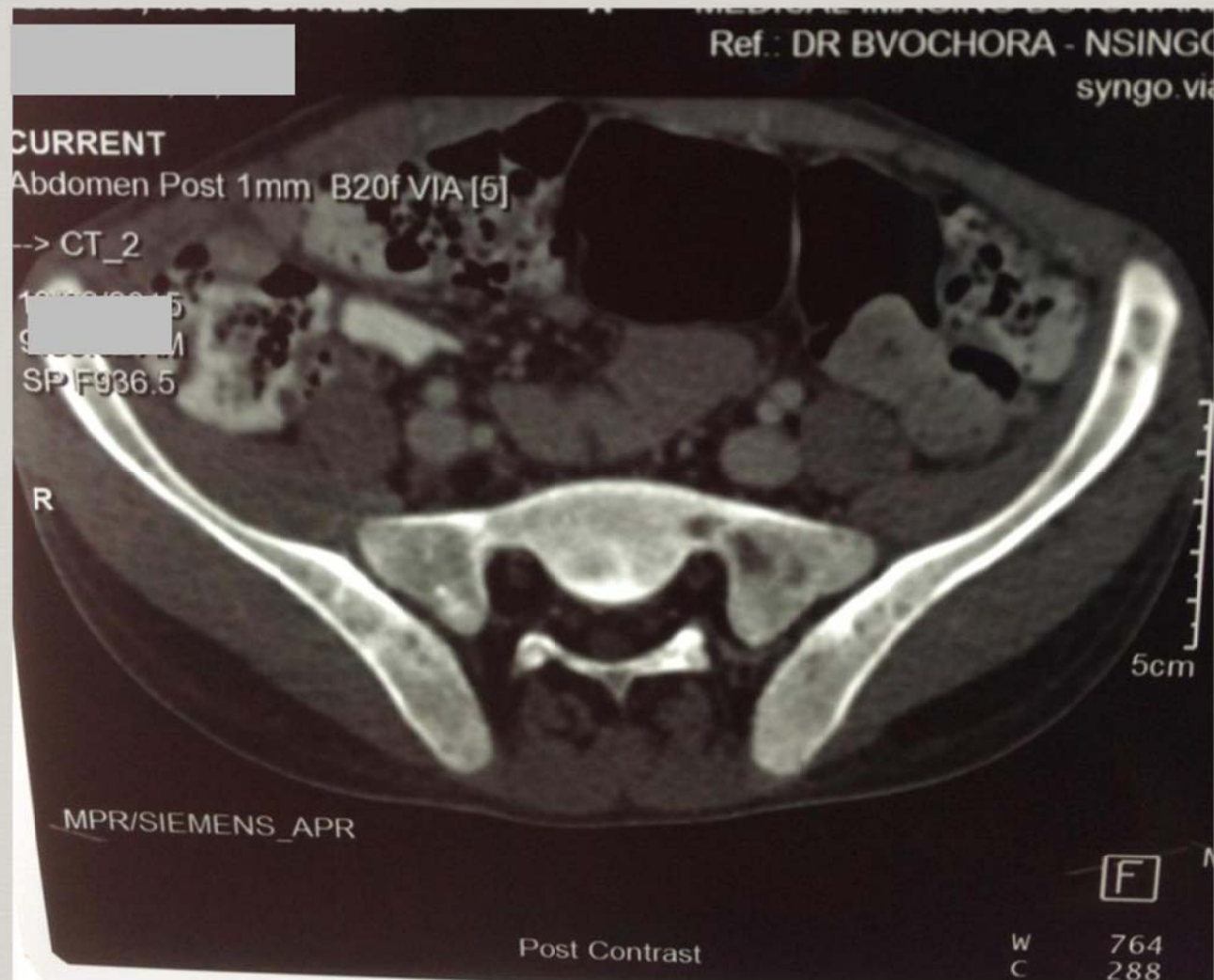











Discussion

When to start chemo ?

Any role for radiation?

Fertility concerns

