



Botswana Multidisciplinary Tumour Board

A 65 year-old woman with dark  
heel mass

21 August 2012

# 65-year old female with dark heel mass

July 2010, Kanye SDA Hospital:

- Over several years ( $\pm 7$  years) developed a dark mass of left heel. Past year mass painful (“pricking pain”) and ulcerated
- PMH: HTN (ACE inhibitor, HCTZ, ASA for primary prevention), declined HIV testing, para 12
- Social: no formal education, village resident
- Exam: hyperpigmented mass of left heel, ulcerated

# 65-year old female with dark heel mass

July 2010, Kanye SDA Hospital:

- Over several years ( $\pm 7$  years) developed a dark mass of left heel. Past year mass painful (“pricking pain”) and ulcerated
- PMH: HTN (ACE inhibitor, HCTZ, ASA for primary prevention), declined HIV testing, para 1 2
- Social: no formal education, village resident
- Exam: hyperpigmented mass of left heel, ulcerated

Impression: probable melanoma

- Referred to surgical clinic

# 65-year old female with dark heel mass

September 2010, Surgical Clinic, Kanye SDA  
Hospital:

- Biopsy performed: 0.8 x 0.5 x 0.4 cm
- Clinical information submitted: “hyperpigmented skin, left heel”

# 65-year old female with dark heel mass

September 2010, Surgical Clinic, Kanye SDA Hospital:

- Biopsy performed: 0.8 x 0.5 x 0.4 cm
- Clinical information submitted: “hyperpigmented skin, left heel”

Pathology assessment, NHL, November 2010:

- “Sections show skin tissue. It shows proliferation of nevus cells in junctional area. No malignancy is seen.”
- Diagnosis: Skin, left heel – Junctional nevus

# 65-year old female with dark heel mass

December 2010, OPD Kayne SDA Hospital

- Mass growing since biopsy
- Biopsy report reviewed with patient, “explained that mass was not malignant”

# 65-year old female with dark heel mass

December 2010, OPD Kayne SDA Hospital

- Mass growing since biopsy
- Biopsy report reviewed with patient, “explained that mass was not malignant”

November 2011, OPD BLH Ramotswa:

- Progressive growth of mass
- Exam: well-circumscribed lesion, ulcerated laterally, no inguinal nodes
- Referred to surgical clinic

# 65-year old female with dark heel mass

December 2011, Surgical Clinic, BLH Ramotswa

- Exam: two satellite lesions, large non-tender left inguinal node
- Impression: "malignant melanoma"
- Plan: referred to PMH for wide excision



# 65-year old female with dark heel mass

February 2012, Surgical ward, PMH Gaborone

- Wide excision of left heel and foot with left lymph node dissection
- Impression: advanced metastatic melanoma

February-May 2012, PMH Gaborone

- Daily wound dressings

# 65-year old female with dark heel mass

## Pathology Assessment, April 2012, NHL

- “Infiltrating, ulcerated malignant melanoma extending into the subcutaneous tissue. Margins free of tumour.”
- Breslow’s thickness: 8.9mm; Clark’s level: V
- 7 of 7 lymph nodes with metastatic melanoma

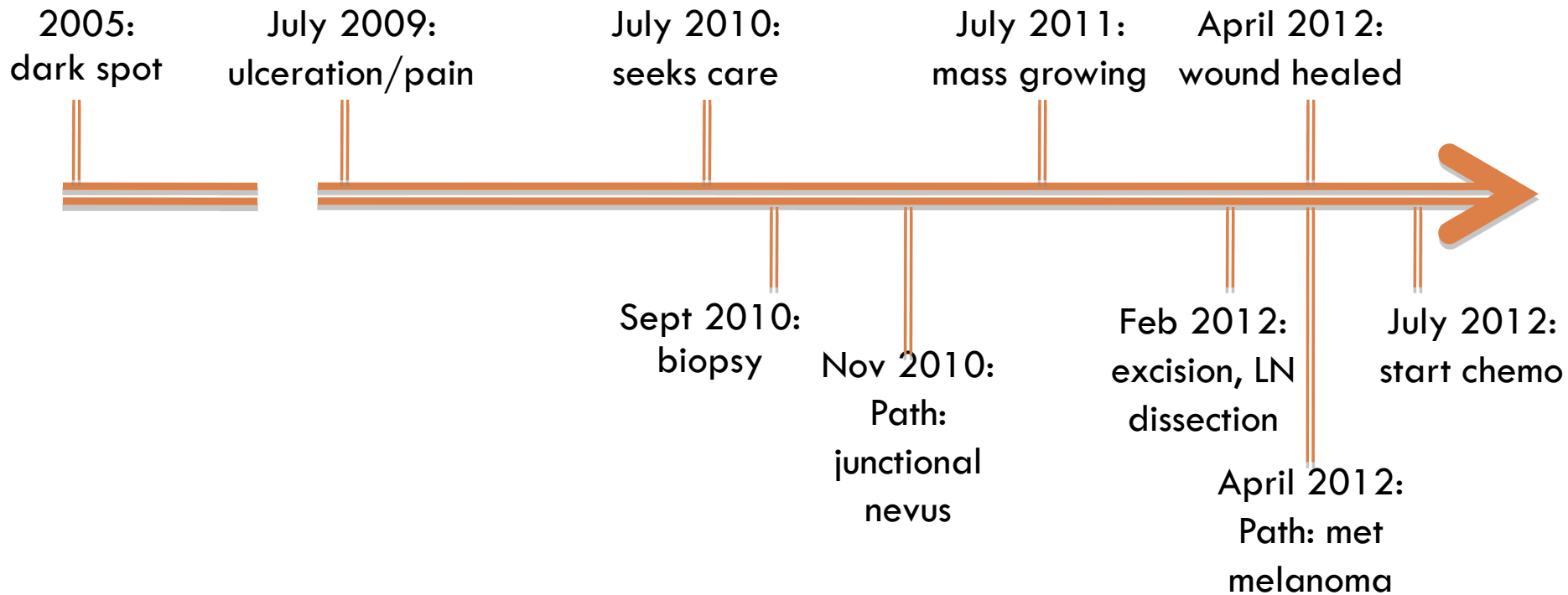
# 65-year old female with dark heel mass

## Oncology, June 2012, PMH

- Exam: healed incisions, no mention of recurrence
- CXR: normal
- Abdominal U/S: normal
- Performance status: 1
- Plan: Dacabazine 150mg/m<sup>2</sup> D1-5 followed by possible radiation therapy

# 65-year old female with dark heel mass

## Timeline:



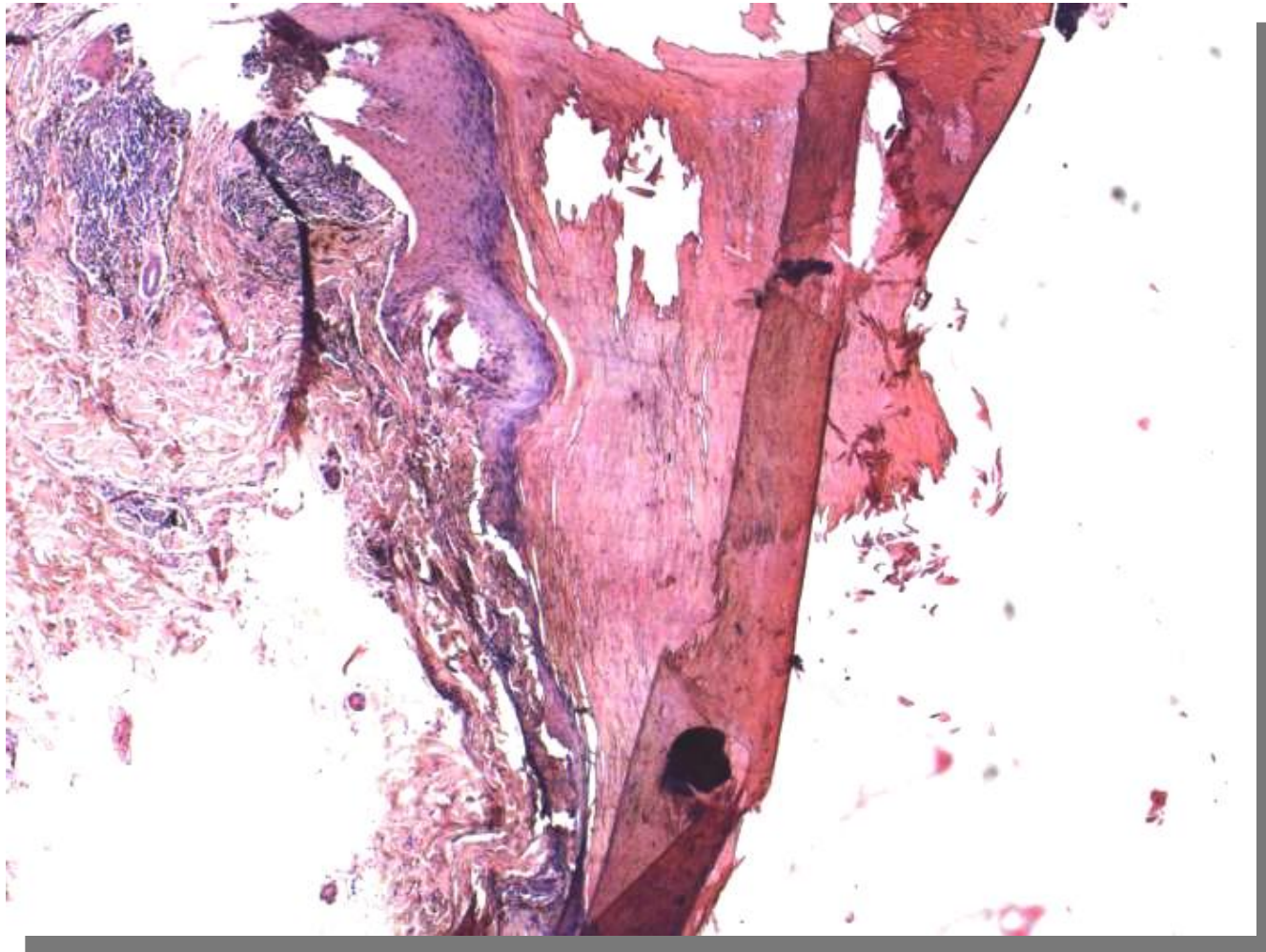


# 65-year old female with dark heel mass



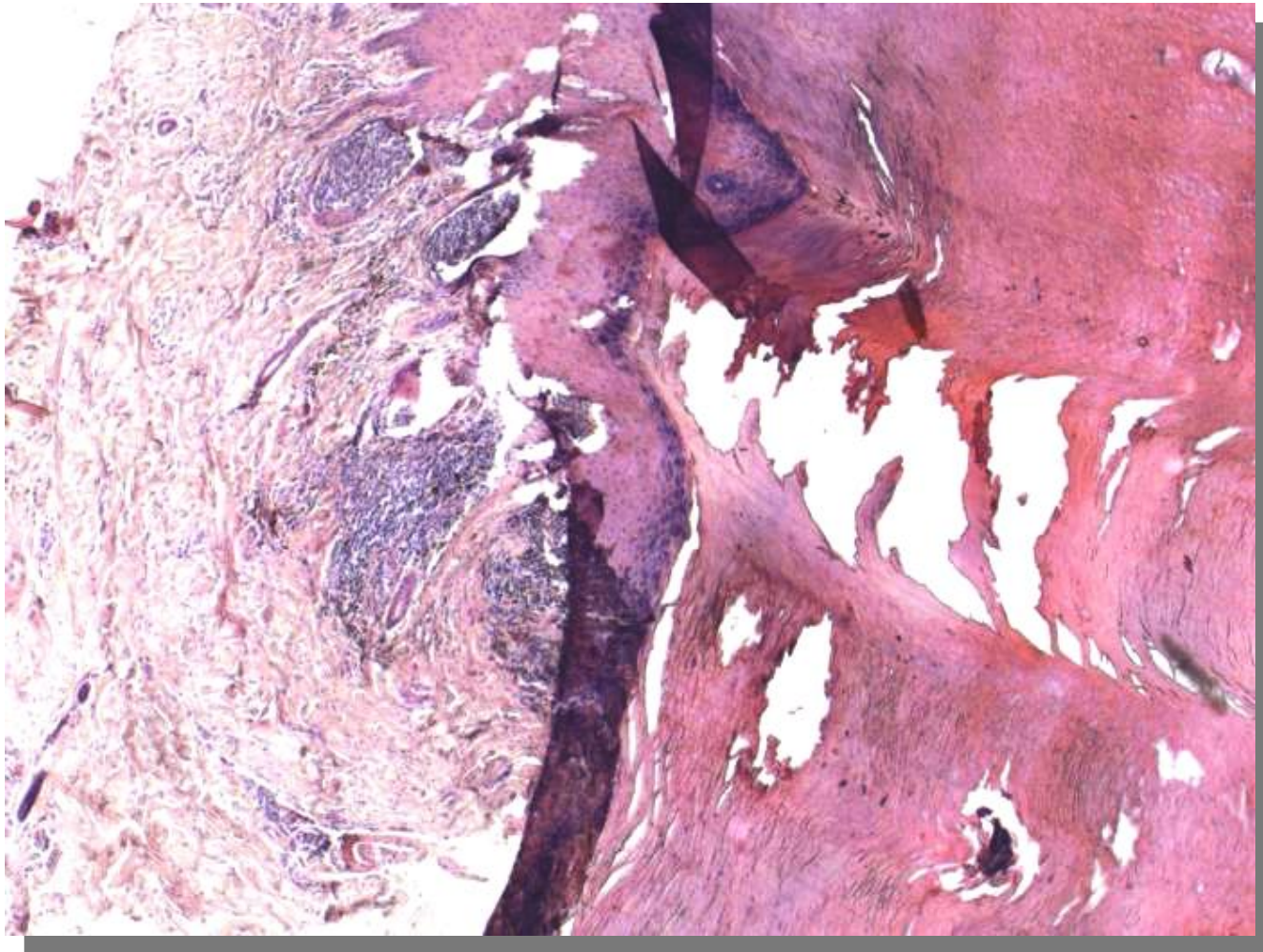
September 2010 biopsy: 2x

# 65-year old female with dark heel mass



September 2010 biopsy: 4x

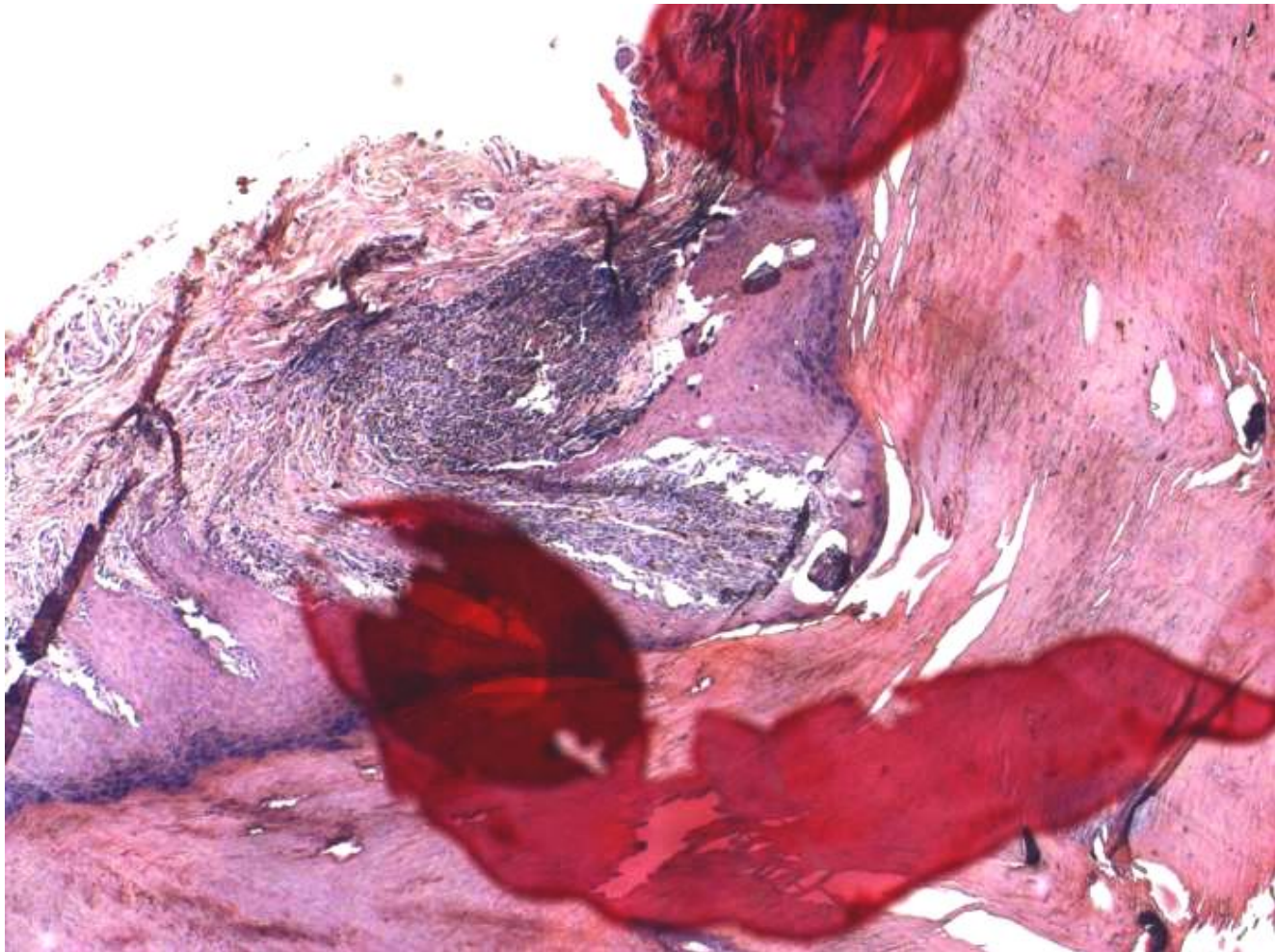
# 65-year old female with dark heel mass



September 2010 biopsy: 4x

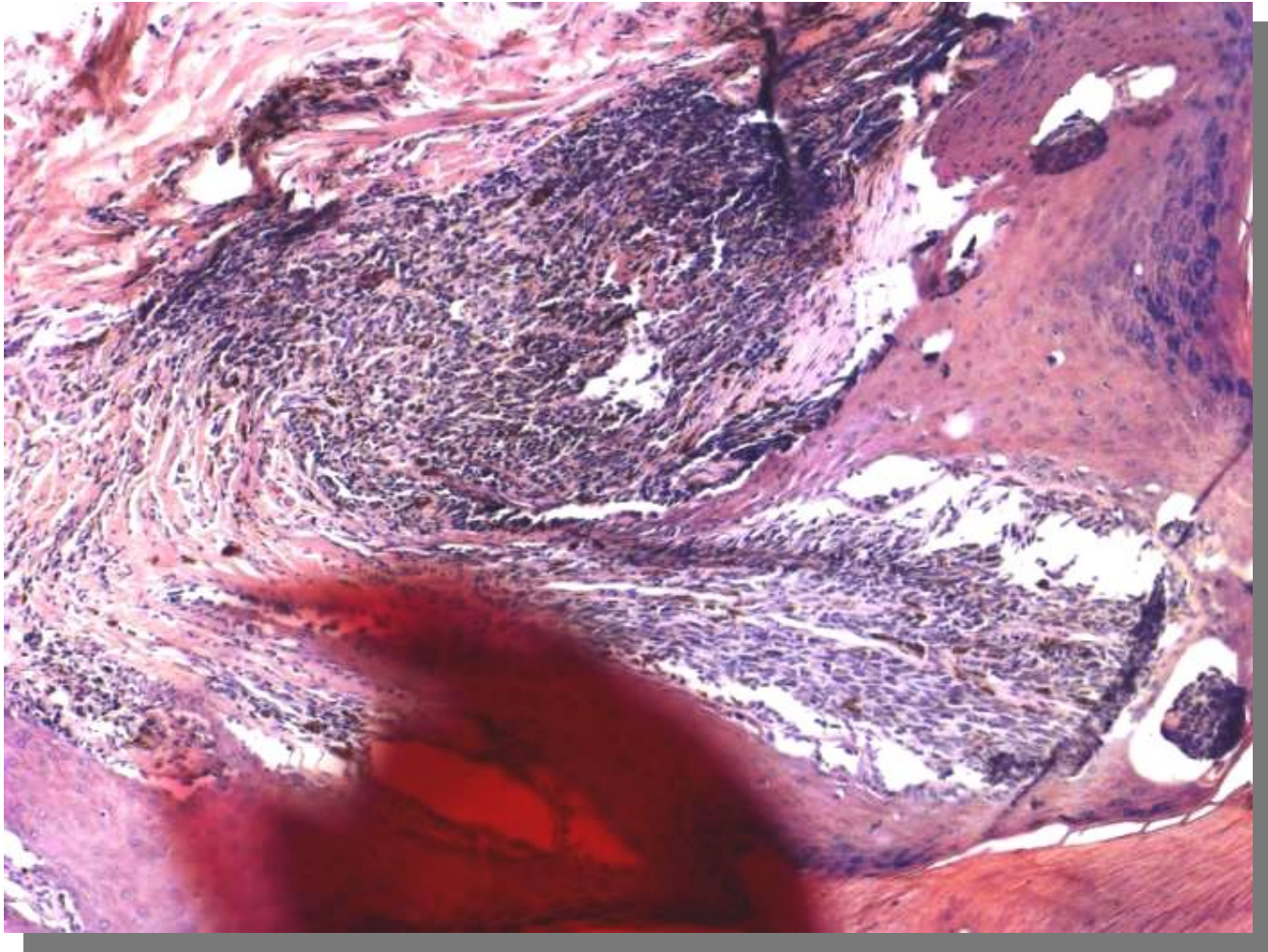


# 65-year old female with dark heel mass



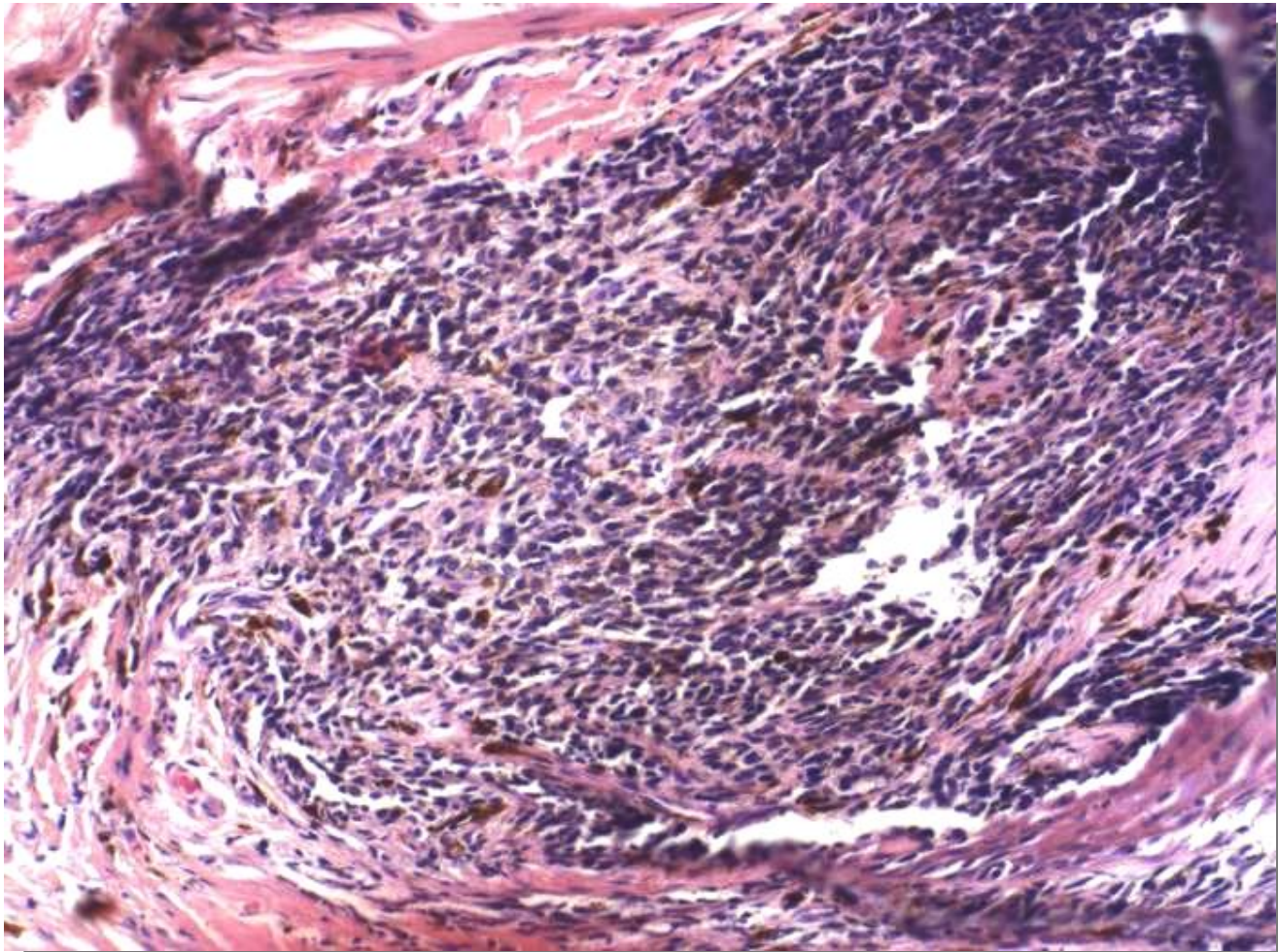
September 2010 biopsy: 4x

# 65-year old female with dark heel mass



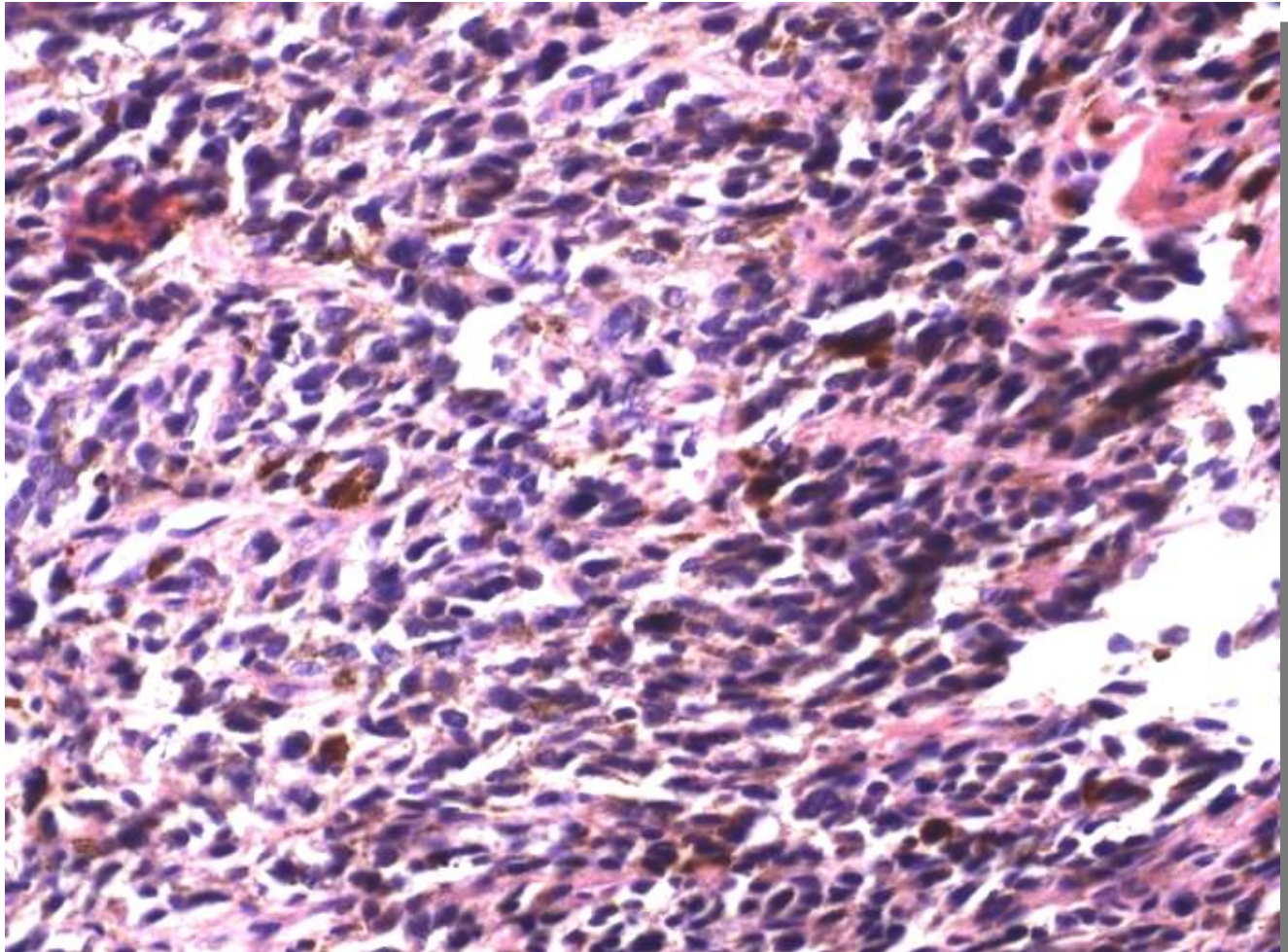
September 2010 biopsy: 10x

# 65-year old female with dark heel mass



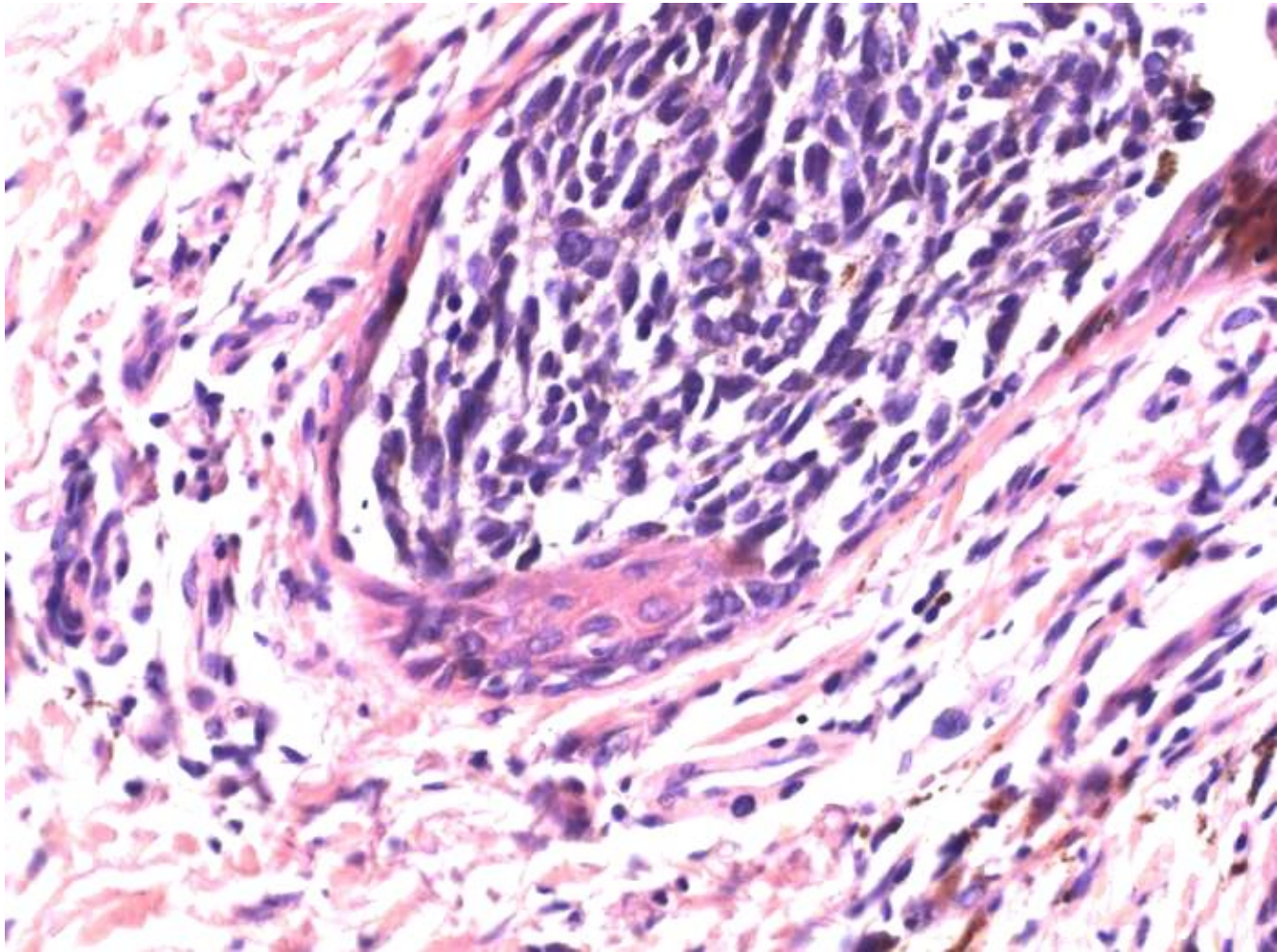
September 2010 biopsy: 20x

# 65-year old female with dark heel mass



September 2010 biopsy: 40x

# 65-year old female with dark heel mass

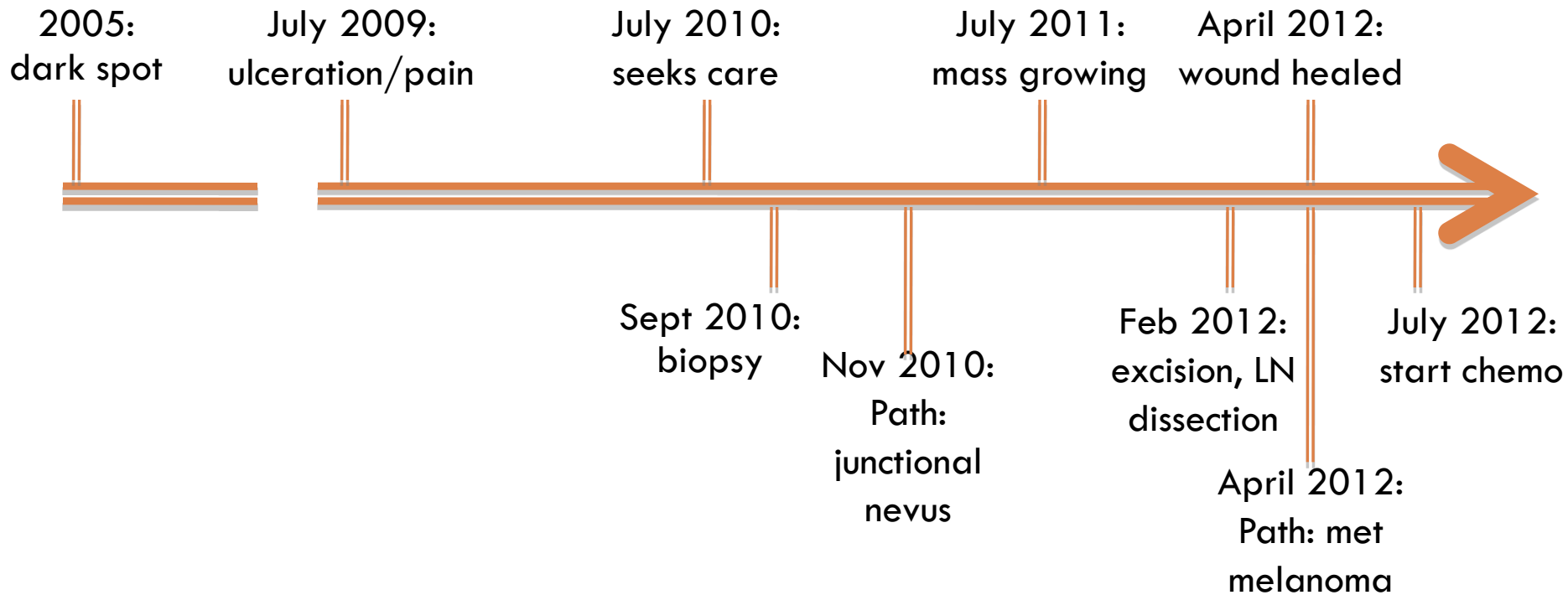


September 2010 biopsy: 40x



# 65-year old female with dark heel mass

## Timeline:







# 65-year old female with dark heel mass

---

**Current Status:**